

PERFORMANCE OF  
BEAUTIFIAN AT  
PRE AND POST  
OPERATION OF  
ABDOMINOPLASTY

PERFORMANCE OF  
AESTHETICIST IN  
THE PRE AND POST-  
OPERATIVE OF  
ABDOMINOPLASTY

SOUZA, Wanessa De Oliveira [1]

[1] Master's student in health sciences, graduating in biomedicine from Faculdade Joaquim Nabuco (UNINABUCO), graduated in Aesthetics from Fundação Mineira de Educação e Cultura (FUMEC), Postgraduate in advanced aesthetics distance education from Uniasselvi Postgraduated in acupuncture from Faculdade da Serran Region (FARESE).  
wanessadeoliveirasouza@gmail.com

SUMMARY

Aesthetics are in evidence. The effectiveness of plastic surgery does not depend solely on its surgical organization, as attention to pre- and post-operative care has proven to prevent probable complications and promote a more satisfactory aesthetic result. In this context, abdominoplasty is a common surgery among women, and it usually occurs after excessive weight loss, loss of muscle and after pregnancy. The purpose of this study was to analyze the beautician's performance before and after abdominoplasty, verifying whether the aesthetic approaches adopted are effective in providing complete recovery for the patient, and avoiding possible complications. If I carry out a bibliographical review on the topic highlighted in books and periodicals, this article is also observational and descriptive, characterized by a prevalence study carried out with a group of eight female patients who previously underwent abdominoplasty surgery. , in the city of Belo Horizonte Minas Gerais. The instrument used for data collection was a structured and investigative questionnaire about the pre- and post-operative period of abdominoplasty. Aesthetics is based on solid scientific concepts and has contributed greatly both pre- and post-operatively, preventing and/or treating complications arising from plastic surgery, also providing a reduction in postoperative apprehension, usual edema resulting from surgical trauma, fibrosis and scars. **Key words:** Abdominoplasty. Pre and post-operative. Electrotherapy. Beautician.

ABSTRACT

Aesthetics are in evidence. The effectiveness of a plastic surgery does not depend solely on its surgical organization because the care with pre and postoperative care has shown a preventive factor for probable complications and the promotion of a more satisfactory aesthetic result. In this context,

Abdominoplasty is a common surgery among women, and its performance usually happens after excessive weight loss, muscle loss and after pregnancy. This study aimed to analyze the performance of the esthetician before and after the abdominoplasty, verifying whether the aesthetic approaches adopted are effective in providing the complete recovery of the patient, and to avoid possible complications. If I carry out a bibliographic review on the topic highlighted in books and periodicals, this article is also observational and descriptive, characterized by a prevalence study carried out with a group of eight female patients who had previously undergone abdominoplasty surgery, in the city of Belo Horizon Minas Gerais. The instrument used for data collection was a structured and investigative questionnaire about the pre and postoperative period of abdominoplasty. Conclusion: Aesthetics is based on solid scientific concepts and has contributed a lot both in the pre and postoperative period, preventing and/or treating complications arising from plastic surgeries, also providing a reduction in postoperative anxiety, recurrent edema of surgical trauma, fibrosis and scarring . **Keywords:**Abdominoplasty. Pre- and post-operative. Electrotherapy. Beautician.

## 1. INTRODUCTION

The rate of aesthetic plastic surgeries is continually growing in Brazil, the search for beauty and a perfect body causes the demand for plastic surgeries to increase every day (SOARES; SOARES; SOARES, 2012). Abdominoplasty is based on the aesthetic correction of the abdominal wall, which may be altered due to several factors, including successive pregnancies, extensive weight loss, excess adipose tissue in the abdominal wall and lower portion of the abdomen and muscle flaccidity (SOARES; SOARES; SOARES, 2012). Regarding the results of abdominoplasty, weight reduction may occur due to the removal of excess skin and adipose tissue, however the abdomens that present the best results are those in which the smallest removals are made (MAUAD; NARESSI; BANZATO, 2011) .

Regarding the postoperative period, several changes can be observed. These include marked edema, ecchymosis in the pubic region and/or flanks, hypoesthesia, seroma below the scar and hematomas. Late consequences of surgery must also be avoided and treated, such as hypertrophic scars, keloids, scar adhesions, pain, muscle flaccidity and weakness, fibrosis and loss of sensitivity (LEAL; SARA, 2017). Post-operative symptoms can be reduced by specialist care through pre- and post-operative procedures and techniques. There is a decrease in edema and hematomas, with the help of vascular and nervous neoformation, in addition to avoiding or reducing

development of hypertrophic or hypotrophic scars, retractions and keloids (LEAL; SARA, 2017).

Given this scenario and based on the offer of various procedures in aesthetic clinics equipped with modern equipment and innovative technological resources, this article hopes to verify the relationship between these pre- and post-operative abdominoplasty procedures and the effectiveness of the surgery. Considering that the success of plastic surgery depends not only on the surgical procedure and the surgeon, but also on a pre- and post-operative approach and scientific technical basis and experience (LEAL; SARA, 2017). The research problem has as its guiding question: How can the beautician act in the pre- and post-operative period of abdominoplasty to reduce or avoid possible complications?

To answer the guiding question presented in the research problem, this study aimed to describe the role of the beautician and the benefits of aesthetic procedures in the pre- and post-operative period of abdominoplasty; and, specifically identify techniques used pre- and post-operatively; describe the results presented in the scientific literature; analyze best practices and demonstrate the importance of the beautician's role in the pre- and post-operative period of abdominoplasties.

This research is justified because it is considered important to appropriate literature to advance knowledge regarding pre- and post-operative abdominoplasty procedures, especially regarding the role of the beautician in this context. This study was organized into an introduction, where the theme, problem, objectives and justification are exposed; theoretical framework, in which the study of literature in relation to the proposed objective is found; methodology, which will describe the methodological path adopted; and, finally, the final considerations, with important findings on the role of the beautician in the pre- and post-operative period of abdominoplasties.

## 2 THEORETICAL FOUNDATION

### 2.1 ABDOMINOPLASTY OR ABDOMINAL DERMOLIPECTOMY.

For Santos, Cândido and Silva (2013), at the beginning of the 19th century, there were changes in the aesthetic standard of beauty, people sought more surgical procedures because it was a method

fast, efficient and requiring little physical effort for the patient. Satisfying these peculiarities, abdominoplasty is a highly requested surgical intervention and is based on the removal of excess abdominal tissue, through a suprapubic incision with displacement of the navel and plication of the recto-abdominal muscles, generally associated with liposuction. , whose purpose is to eliminate excess adipose tissue through thin cannulas, granting body redefinition. Regarding abdominoplasty, table 1 below presents the conceptual approach given by several authors.

**Chart 1 - Definitions of abdominoplasty.**

Reference	Definition
Migotto (2012)	Abdominoplasty is an aesthetic and functional correction of the abdominal wall, due to changes caused by muscle flaccidity, excessive weight loss, successive pregnancies, abdominal diastasis, extensive deposits of adipose tissue in the abdominal wall and hernias.
From Araújo; Cabral (2011)	Abdominoplasty is a surgical, plastic and aesthetic intervention of the abdomen carried out under general or epidural anesthesia with sedation, at the discretion of the surgical-anesthetic team and generally lasts between 3 and 5 hours. It is characterized by the extraction of lipodystrophy found in the lower abdomen, the removal of tissue flaccidity around the navel and stretch marks.
Souza; Harada; Bolognani (2017).	Abdominoplasty can be combined with liposuction, with the aim of eliminating excess fat through thin cannulas, enabling a total redefinition of the abdomen.
Lange (2012)	Abdominoplasty consists of the following procedures: A low transverse incision; Displacement of the skin to the xiphoid process and costal margin; Intervention of the entire musculoaponeurotic wall; Production of a new navel, a process called omphaloplasty, and the removal of excess skin and fatty tissue; Placement of drains; fixing the lower portion of the flap and suturing the flap in the suprapubic region, with absorbable thread.
Borges; Scorza; Jahara (2010)	Abdominoplasty is indicated for patients with moderate or severe skin flaccidity, correlated with localized lipodystrophy, and abdominal wall hernias may be present. Its objective is to restore body contour, eliminating excess skin and adipose tissue, when possible; and correct muscle flaccidity and possible hernias. It is contraindicated if the tissue flaccidity is small, and in lung patients, diabetics and smokers as there is a risk of tissue necrosis.
Fonseca <i>et. al.</i> (2018)	The surgical procedures used to modify the contour and shape of the abdomen include abdominoplasty, also called classic dermolipectomy; modified abdominoplasty or "mini abdominoplasty" and circumferential abdominoplasty.
Chi <i>et. al.</i> (2016)	The abdominoplasty scar is exponentially unsightly and harmful, despite this, the surgery is performed too frequently.
DaSilva <i>et. al.</i> (2014)	Among the abdominoplasty techniques, the mini abdominoplasty without removing the navel stands out, which only treats the portion below the navel, so there is no need to reposition it; mini abdominoplasty with detachment of the navel, suturing it 2 to 3 centimeters below its original position; the classic abdominoplasty that treats the entire anterior abdomen and creates a new

	navel hole; abdominoplasty with small detachment and lipoabdominoplasty involves abdominal liposuction, releasing the muscles without damaging the vessels; The lower skin excess is removed and a new umbilical orifice is created.
In Macedo It is In Oliveira (2010)	During abdominoplasty, the sutures are internal and external and will be removed according to medical planning in the postoperative period. Drains are generally placed and can be removed between 24 and 96 hours post-operatively, with medical advice. The area is bandaged and a surgical shaper with cotton foam is placed in the first 30 to 60 days.
Deterling <i>et. al.</i> (2010)	Abdominal imperfections can be aesthetic and/or functional changes. Aesthetic limitations are those that alter the body contour and are mainly due to the flaccidity of the abdominal wall, the accumulation of adipose and muscle-aponeurotic weakening. Most common indicative factors for abdominoplasty.
Di Martino <i>et. al.</i> (2010)	Abdominal plastic surgery aims to correct deformities in the abdominal wall. These changes affect the integumentary coverage and the musculoaponeurotic structure, so abdominoplasty seeks to achieve a standard compatible with what is considered "normal" for body contouring.

Source: Developed by the author.

Corroborating the ideas of the authors above, I define abdominoplasty as a procedure in which excess fat and skin is removed from the abdomen, restoring weakened or separated muscles, creating a harmonious and toned abdominal profile. Knowledge about surgical aspects is essential for a beautician to perform well in the pre- and post-operative period of abdominoplasty.

## 2.2 POSTOPERATIVE COMPLICATIONS

Regardless of the techniques applied, abdominoplasty is still a surgery with a high rate of complications, although it is easy to handle and has a good prognosis. Postoperative complications include hematoma, infection, dehiscence, irregularities, depressions, adhesions, edema, fibrosis, poorly positioned scars, hypertrophic and keloid scars, ecchymosis, necrosis, seroma, depressions and skin excesses. These are situations that may vary according to each surgery and the technique applied (LEAL; SARA, 2017; BORGES; SCORZA; JAHARA, 2010; DA SILVA, 2014; SOARES; SOARES; SOARES, 2012).

Such inconveniences could be avoided, in the great prevalence of cases, by the correct indication of the surgery and by respecting the technical principles that guide it, in addition to the specific care that must be taken both pre-, inter- and post-operatively,

both by the doctor and by the multidisciplinary team that is generally monitoring the patient (YACOUB; BAROUDI; YACOUB, 2012).

Seroma formation is the most frequent local complication in abdominoplasty. When present, the treatment of seromas is carried out by the medical team, generally speaking, this complication is resolved without major problems. In cases where the seroma is large, or even persistent after multiple punctures, new surgical intervention, occasionally, and the insertion of drains are necessary (LEAL; SARA, 2017). Infection is the second most common local complication observed in abdominoplasties, in the form of surgical wound infection and/or infected seroma (LEAL; SARA, 2017; NEAMAN *et. al.*, 2013).

Immunosuppressed, malnourished and diabetic patients are more prone to postoperative infection, especially if associated with obesity (MURSHID *et. al.*, 2010; LOYAL; SARA, 2017). Smoking also increases the risk of infection, due to the vasoconstriction resulting from the components present in cigarettes, which modify skin microcirculation, reduce intrinsic cellular immunity, in addition to tissue necrosis and occult seroma. The infection must be managed by the medical team by carrying out a diagnosis and administering antibiotics. When present, the classic signs of infection are pain, heat, redness, induration and erythema (MURSHID *et. al.*, 2010; LOYAL; SARA, 2017).

Cutaneous necrosis presents itself in a simple form, such as epitheliolysis, generally self-limited, and small dehiscences, up to extensive necrosis. Isolated necrosis of the navel, in turn, may occur in rare cases, generally resulting from excessive plication around this structure (LEAL; SARA, 2017; NEAMAN *et. al.*, 2013). Smoking triples the chances of developing skin necrosis and is therefore the main risk factor for necrosis. The patient must give up smoking for at least two months before surgery (MURSHID *et. al.*, 2010; LOYAL; SARA, 2017).

It is recommended to avoid prolonged surgeries and association with other aesthetic surgeries at the same time, as they increase the risk of postoperative morbidity (LEAL; SARA, 2017; NEAMAN *et. al.*, 2013). Minimal necrosis and/or dehiscence must be handled carefully, they are generally treated with bandages, ointments and medicinal moisturizers, and recovery lasts from weeks to months. Wide and deep necrosis must be treated with surgical debridement in order to stimulate

formation of granulation tissue to close the lesion. Resources such as hyperbaric oxygen therapy and negative pressure therapy have proven advantages, and can be indicated when necessary (LEAL; SARA, 2017).

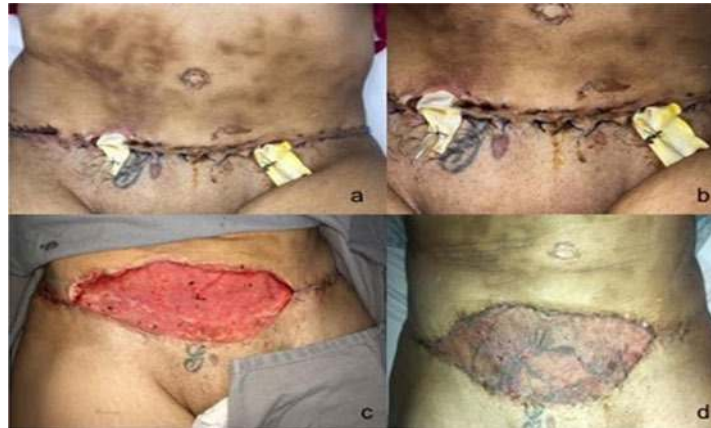

Figure 1: Infected seroma with necrosis in a patient on the twentieth day after liposuction and abdominoplasty. A: Tissue necrosis; B: Infected seroma; C: Granulation tissue derived from debridement and negative pressure therapy; D: Final product after grafting. Source: (LEAL; SARA, 2017; NEAMAN *et. al.*, 2013).

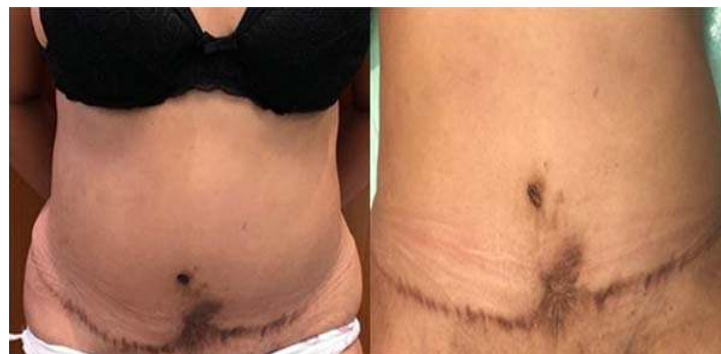

Figure 2: Asymmetry and unsightly scar post-necrosis after abdominoplasty associated with liposuction. Patient in the late postoperative period of liposuction and abdominoplasty with a history of smoking and use of a tight belt in the postoperative period. Managed with chemical debridement and antibiotics, it developed an unsightly scar due to secondary intention and poor positioning of the navel due to scar retraction. Source: (LEAL; SARA, 2017; NEAMAN *et. al.*, 2013).

Hematoma is the third most common local complication in abdominoplasties. Pressure changes during and after surgery, inadequate hemostasis and pre-existing coagulopathies are considered the main risk factors for the occurrence of hematoma. There were no reports relating an increased risk of hematoma when associated with liposuction. The hematoma is generally asymptomatic or undiagnosed, and does not cause serious consequences. However, large bruises can evolve with

hemodynamic instability and compression of the detached flap, which can lead to skin necrosis, and should be promptly explored (Figure 3) (SAMRA *et. al.*, 2010).

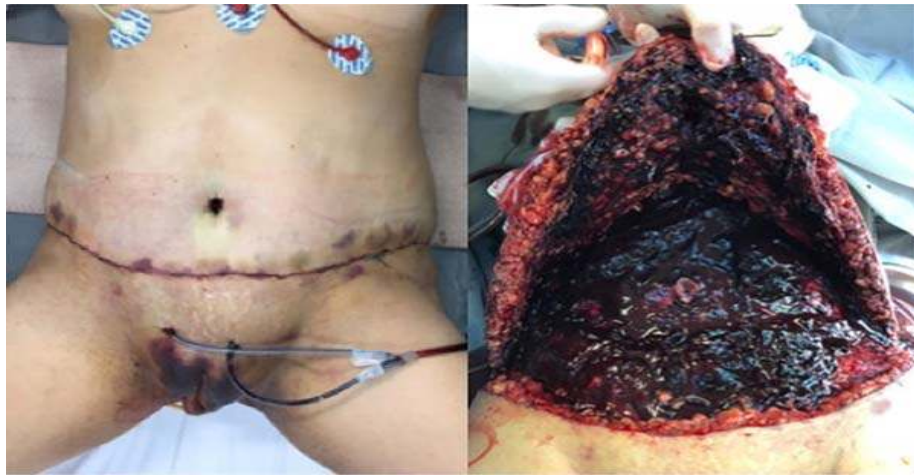

Figure 3: Large hematoma with hemodynamic instability in the recent postoperative period of abdominoplasty  
Source: (SANTOS; CÂNDIDO; SILVA, 2013).

Keloid scars must be approached with caution so that the injury does not worsen. Body contour asymmetry may be due to poor results from plication of diastasis of the rectus abdominis muscles. This can occur due to suture laxity, rupture or even excessive tension and consequent ischemia (LEAL; SARA, 2017). Some authors recommend two-layer plication in order to form a more persistent fibrosis, however, there is a theoretical risk of ischemia and consequent aponeurotic dehiscence (LEAL; SARA, 2017).

Macedo and de Oliveira (2010) describe fibrosis as ripples that appear in the injured area, to a greater or lesser extent. This change is characterized by the formation of collagen in a disorganized way, causing the production of ripples, which cause tightness and pain. Fibrosis is correlated with the presence of deficiencies in healing due to excessive production of the extracellular matrix and the high rate of mitosis of dermal fibroblasts.

To stop the formation of fibrosis, it is recommended to intervene therapeutically immediately, at the beginning of the response to tissue aggression, when collagen synthesis occurs. Accumulation of localized adipose, incompetent skin resection and poor scar positioning are also factors in postoperative dissatisfaction. Cases of chronic pain usually occur from damage to the lateral femoral cutaneous nerve. To this end, careful dissection close to the anterior superior iliac spine is advised (MACEDO; DE OLIVEIRA, 2010). The pain appears under the

form of paresthesias and “stings”, is generally self-limited. In refractory cases, surgical exploration aimed at releasing the enclosed nerve or resection of a neuroma may be necessary (LEAL; SARA, 2017).

Edema is an excessive accumulation of fluids in the tissues, being highly beneficial, as it is the body's response signaling that there are signs of tissue repair. The hematoma occurs due to the blood that accumulates in the injured region, resulting from the rupture of the capillaries in the affected area. . Seroma occurs due to excessive displacement of the abdominal flap and is characterized by excess yellow fluid that is retained in the subcutaneous tissue (DI MARTINO *et. al.*, 2010; SOUZA; HARADA; BOLOGNANI, 2017).

Another consequence of tissue aggression is the fibrosis that appears beneath the skin in the proliferative phase that lasts up to 21 days after surgery. As the healing process progresses, the granulation tissue transforms into a more fibrous and less vascular tissue. until it becomes dense, fibrous tissue (ROBERTSON, 2011). This new tissue is initially fragile and can later become rigid and painful (BARROS, 2017; BRAVO *et. al.*, 2013; ANGELIM, 2010; CHI *et. al.*, 2016).

### 2.3 AESTHETIC RESOURCES

In harmony with the thoughts of Vieira and Netz (2012), in addition to surgical organization, the effectiveness of plastic surgery also depends on intervention and care before and after surgery, preventing likely complications and promoting a more satisfactory aesthetic result. New aesthetic intervention protocols have been used to reduce the postoperative complications mentioned above.

The main aesthetic therapeutic resources used in these protocols are manual (manual lymphatic drainage - MLD and classic massage), kinesiotherapy, ultrasound, therapeutic laser, electrotherapy (transcutaneous electrical nerve stimulation (TENS), radiofrequency, vacuotherapy, cryotherapy, phototherapy, thermotherapy, LEDs, among others (LEAL; SARA, 2017; BORGES; SCORZA; JAHARA, 2010).

### 2.3.1 Manual lymphatic drainage

The fundamental maneuvers of Manual Lymphatic Drainage (MLD) were published by Vodder in 1936, they were classified into vertical circles, pumping, traction and torsion movements. For Zanell; Ruckl and Voloszin (2011) Vodder's technique is based on monotonous, slow, harmonious, smooth and rhythmic movements, always respecting the direction of the superficial lymphatic flow towards the terminal (subclavicular), where the lymphatic circulation ends. In agreement with Godoy and Godoy (2020), manual lymphatic drainage is one of the main pillars in the treatment of lymphedema. It was developed based on observational research and published in the 60s and 70s, fostering interest in the medical field due to the results obtained.

Zanell; Ruckl and Voloszin (2011) mention that to expand the practical maneuvers of DLM, they considered the techniques of Vodder and others who continued research in the area and managed to verify the efficiency of some maneuvers in DLM, enhancing the results.

### 2.3.2 Ultrasound

Ultrasound (US) at a frequency of 3MHz is extremely used in the inflammatory phase of healing, it acts by promoting tissue repair in the injured area, promoting angiogenesis, granulation tissue, the number of fibroblasts and collagen synthesis, in addition to reducing in the amount of leukocytes and macrophages in the area. There is evidence reporting the effectiveness of US in the different phases of tissue repair. Its use in the post-operative period of plastic surgery contributes to the reabsorption of hematomas, reducing the chances of fibrosis formation, preventing the formation of hypertrophic scars and keloids, also improving cellular nutrition, reducing edema and pain, due to improved blood circulation. and lymphatic (SANTOS; CÂNDIDO; SILVA, 2013).

The use of post-operative heat, from thermal therapeutic resources, aims to improve the quality of scar tissue, treating fibrosis and adhesions. Its use should begin when the presence of fibrosis is assessed, normally in the proliferative phase. However, to reach the therapeutic level of heating the temperature must

be between 40° and 45°, below this level the effects of warming are insufficient (SANTOS; CÂNDIDO; SILVA, 2013).

US promotes, through its thermal and non-thermal effects, an increase in the speed of tissue repair and healing of injuries, an increase in blood flow and tissue extension capacity, the deterioration of calcium reserves and a reduction in pain. , through changes in nerve conduction and cell membrane permeability. In addition to the benefits already mentioned, the reabsorption of hematomas stimulated by US is essential in the first phase of PO treatment, preventing fibrosis from occurring as a result (SANTOS; CÂNDIDO; SILVA, 2013; FONSECA, 2018).

### **2.3.3 Cryotherapy**

Cryotherapy is another thermal resource that contributes during the post-operative period of plastic surgery. It is noted that the cold causes vasoconstriction, reducing regional blood flow and consequently, hemorrhage in the traumatized area, therefore limiting tissue trauma. Its action is referred to the immediate vasoconstriction of arterioles and venules, and also the decrease in cellular metabolism and vasoactive substances, such as histamine. It is a highly used technique, low cost, relatively simple to use and competent in reducing pain, edema and inflammation (SANTOS; CÂNDIDO; SILVA, 2013; FONSECA, 2018).

### **2.3.4 Laser**

Laser is a word of English origin and its abbreviation Light Amplification by Stimulated Emission of Radiation means the emission of light by radiation. Some researchers saw its potential in low-intensity radiation, causing some factors such as photo-stimulation of the tissue healing process (SANTOS; CÂNDIDO; SILVA, 2013; FONSECA, 2018). The properties transmitted by laser light can be invisible, or from an infrared lamp (SANTOS; CÂNDIDO; SILVA, 2013; FONSECA, 2018). The physiological effects of using laser are to increase blood circulation

arteries, venules, improve circulation, regeneration, repair, recruit collagen, angiogenesis SANTOS; CANDID; SILVA, 2013; FONSECA, 2018).

#### 2.3.4 Phototherapy and LEDs

The use of laser or LED phototherapy for the inflammatory process promotes an increase in lymphatic flow and the performance of neutrophils and macrophages, thus reducing edema and promoting the immune response; increases the formation of collagen, stimulates the formation of fibroblasts, increases lateral circulation and micro circulation (ESPER,2010). The therapist must define the dosage of energy to be deposited in the tissue, taking into account the type of pathology, the depth of the injury, type of injury, type of tissue, the objective of therapy, skin color, age of the patient and his systemic condition, among other items analyzed in the anamnesis, this must be between 1 and 6 J/cm<sup>2</sup> (DETERLING *et. al.*, 2010).

According to Ramos *et. al.*(2017), the red LED can be used after plastic surgery trauma, it reduces the time for resolution of erythema, edema and hematomas, by half the time to a third, due to its effective anti-inflammatory action. Energy density is one of the most important parameters of laser therapy. Phototherapy can be stimulating or inhibitory, depending on the dose used (RAMOS *et. al.*, 2017). Irradiation with non-coherent light is more cost-effective, as it has a lower cost and is similar in effectiveness to lasers. In this way, LEDs are recently being used as an alternative to therapies that use low-intensity lasers to control edema (RAMOS *et. al.*, 2017).

### 3 METHODOLOGY

To fulfill the research objective, a bibliographical review was carried out on the topic highlighted in books and periodicals. Articles in Portuguese, Spanish and English were considered for analysis. The texts were analyzed in order to obtain consistent information regarding the role of the beautician in the process of treatments carried out before and after abdominoplasty. an analysis of titles and abstracts was conducted to obtain potentially relevant articles for the review. For inclusion criteria, articles should be related to abdominoplasty plastic surgery and

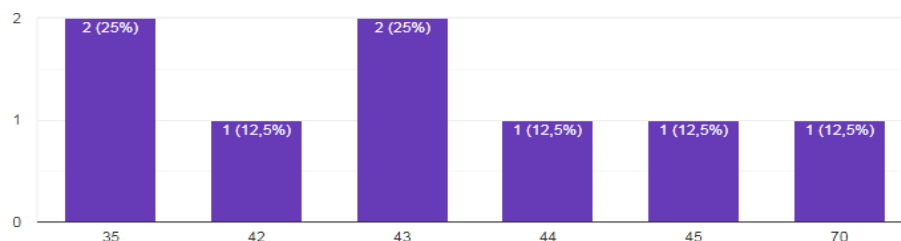
liposuction, aesthetic modalities in general and their effects on pre- and post-operative treatment. Articles that did not refer to the researched topic or that were not available for reference were disregarded.

This article is also qualitative and descriptive. It is characterized by a prevalence study carried out with a group of eight female patients who previously underwent abdominoplasty surgery, in the city of Belo Horizonte Minas Gerais. The first contact was made by telephone to schedule the sending of the questionnaire. All agreed to participate in the research. The instrument used for data collection was a structured and investigative questionnaire about the pre- and post-operative period of abdominoplasty.

#### 4 RESULTS AND DISCUSSIONS

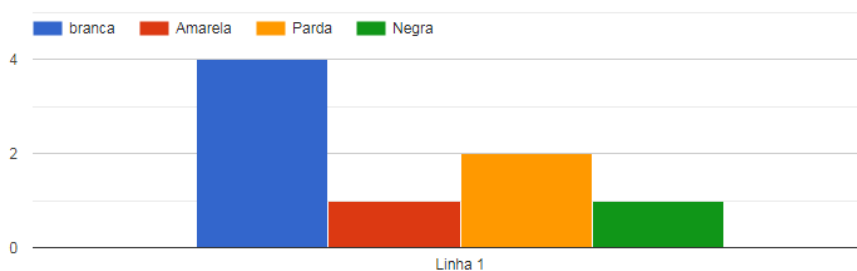
Below are graphs relating to the answers provided by the interviewees, which will be discussed in the next subtopic.

**Figure 4: Age group**



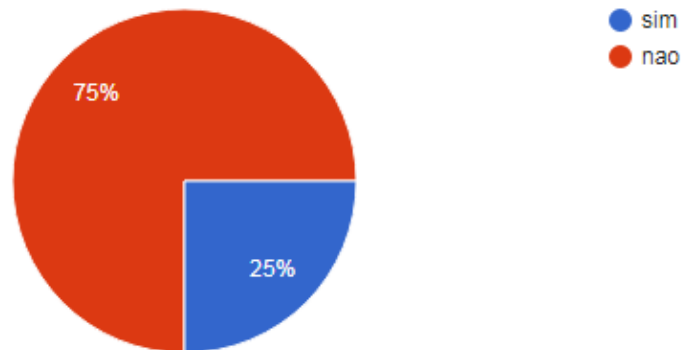
Source: Research data

**Figure 5: Ethnicity Information**



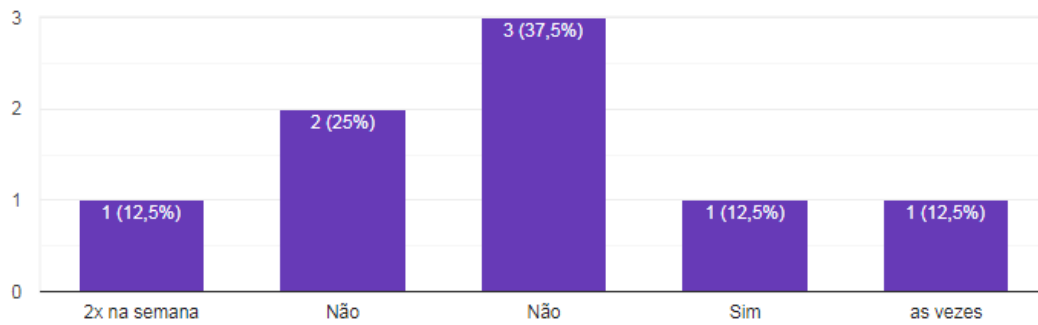
Source: Research data

**Figure 6: Smoking Information**



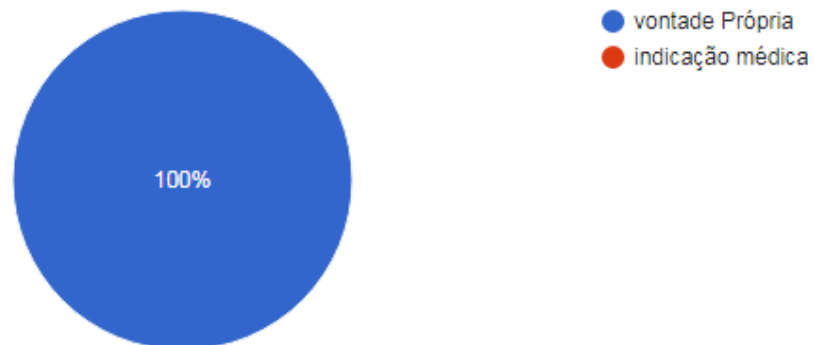Source: Research data.

**Figure 7: Information on alcohol consumption**



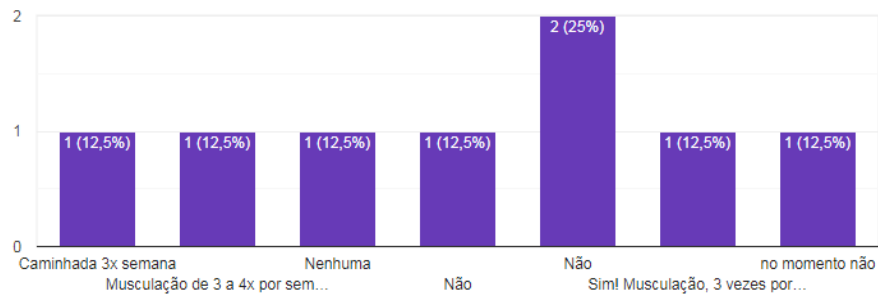
Source: Research data

**Figure 8: Factor that led her to have an abdominoplasty**



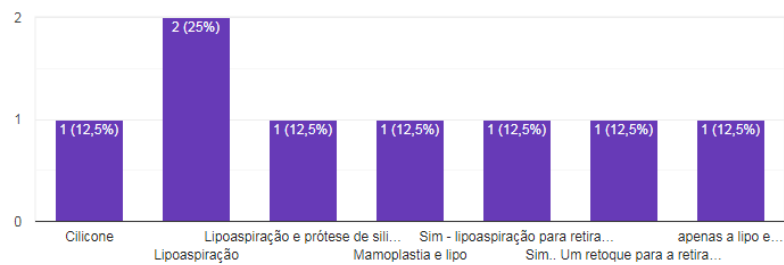
Source: Research data

**Figure 9: Practice of physical activities**



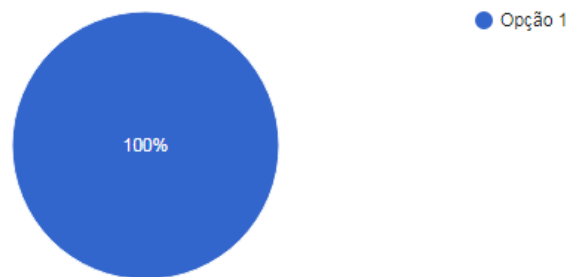
Source: Research data

**Figure 10: Procedures associated with abdominoplasty**



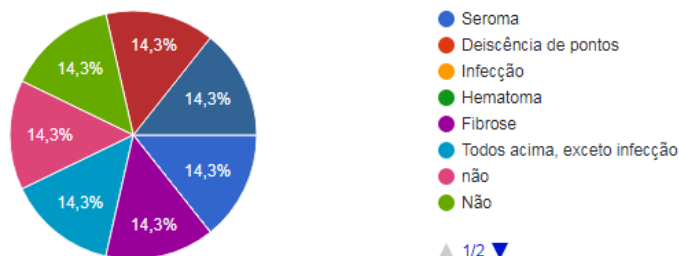
Source: Research data

**Figure 11: Beautician's role**



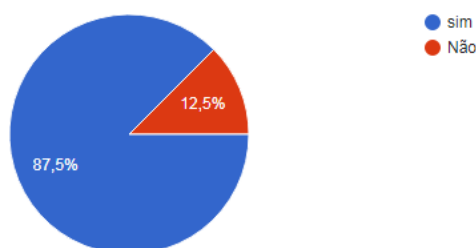
Source: Research data

**Figure 12: Post-operative complications**



Source: Research data

**Figure 13: Final satisfaction**



Source: Research data

#### 4.1 CRITICAL ANALYSIS OF RESULTS

From the questionnaire sent to the interviewees electronically, it was possible to quantify that a total of eight female patients were willing to answer all the questions, among them, two were 35 years old, one was 42 years old, two were 43 years old, one was 44 years old, one 45 years old and one 70 years old. Four are Caucasian, one is yellow, two are brown, and one is black. Vieira and Netz (2012) mention that Brazil is ranked second in the world in terms of the number of plastic surgeries. After asking about cigarette consumption, only two stated that they had the habit of smoking daily.

Murshid *et. al.*, (2010); Leal and Sara (2017) State that the habit of smoking considerably increases the risk of infections, which is explained by the vasoconstriction caused by the components of cigarettes, altering skin microcirculation, decreasing immunity and can cause tissue necrosis and occult seroma, smoking and the main risk factor for

appearance of post-operative complications which triples the chances of developing skin necrosis, they advise that the patient should give up smoking at least two months before the surgical procedure.

We asked about the consumption of alcoholic beverages, and among them, only one mentioned using alcoholic beverages twice a week, one stated that they used it once in a while, leaving five who stated that they did not use alcohol. In our research, all eight participants stated that they had chosen abdominoplasty of their own free will, without any prior medical indication. For Santos, Cândido and Silva (2013), at the beginning of the 19th century, there were changes in the aesthetic standard of beauty, people sought more surgical interventions because it was a quick, effective and effortless method.

Vieira and Netz (2012) state that the media is responsible for proposing a "beauty standard". Plastic surgeries, when carried out with appropriate indications, can provide transformations, helping people improve their self-esteem and thus their quality of life.

Borges; Scorza; Jahara (2010) mentioned that abdominoplasty is indicated for patients with moderate or severe skin flaccidity associated with localized or generalized lipodystrophy, with or without hernias of the abdominal wall, with the aim of reestablishing the body contour, eliminating excess skin and adipose tissue. , when possible; and correct muscle flaccidity and possible hernias. It is contraindicated when there is minimal tissue flaccidity, in patients with lung disorders, diabetes and heavy smokers due to the risk of tissue necrosis. Yacoub; Baroudi and Yacoub (2012) state that postoperative complications can be avoided, in the vast majority of cases, by correctly indicating the surgery and respecting the technical principles that guide it, also associated with specific care, which must be taken both pre-, inter- and post-operatively, both by the doctor and the multidisciplinary team that is generally monitoring the patient.

Regarding the practice of physical activity, four stated that they practiced it three times a week, and four mentioned that they did not perform any type of activity, classifying themselves as sedentary. Regarding the time elapsed since the surgery, four mentioned that it was performed less than a year ago, two to four years, one to 12 years and one to 15 years. The research carried out revealed that all of them had undergone some procedure associated with

abdominoplasty, two with breast implants and liposuction and six with liposuction. Souza; Harada; Bolognani (2017) say that abdominoplasty can be associated with liposuction, with the intention of removing excess fat through thin cannulas, allowing a global redefinition of the trunk.

According to the interviewees, two did not have any pre-operative medical recommendations and six had pre-operative medical recommendations, such as weight loss, laboratory tests, not using cigarettes or alcoholic beverages and fasting for 12 hours before surgery. Of these six patients, one highlighted the medical recommendation to undergo six lymphatic drainage sessions before surgery. After undergoing abdominoplasty surgery, the medical recommendations given to patients were rest for 30 days, use of anti-inflammatory drugs and pain relief medication, sleeping in the supine position, walking slightly bent forward for 15 days, use of straps and beginning of Lymphatic drainage with at least fifteen sessions.

According to Borges; Scorza; Jahara (2010) after surgical intervention it is recommended: - The use of an elastic belt for a period of 45 to 60 days; 9 - Rest for 24 to 48 hours, until the drains are removed; - Walk with the torso slightly bent; - Avoid activities that require physical effort. Vieira and Netz (2012) mentioned that these recommendations are important for the individual's own well-being and correct recovery.

With regard to lymphatic drainage, it can be observed that the participants reported: one stated that she only had one session; one stated that she had five sessions; one stated that she held eleven sessions; one stated that she held fifteen sessions; two others stated that they performed twenty sessions each; one stated that she held forty sessions; Among the eight participants, only one did not use an ultrasound device, and one used both ultrasound and radiofrequency.

From what it was possible to analyze, only two did not mention suffering any complications in the postoperative period, one stated that she had suffered several complications, only had no infection, and the other five patients had all the most known complications, such as fibrosis, infection, dehiscence of stitches and seroma. Due to the complications, it was necessary for 2 of the 8 women to stay away for a period longer than 30 days, one returned to work after forty-five days and the last returned after sixty days.

Loyal; Sara (2017); Borges; Scorza; Jahara, (2010); Da Silva, (2014); Soares; Soares; Soares, (2012) reported that postoperative complications such as hematoma, infection, dehiscence, irregularities, depressions, adhesions, edema, fibrosis, poorly positioned scars, hypertrophic and keloid scars, ecchymosis, necrosis, seroma, depressions and skin excess. These are situations that may vary according to each surgery and the technique applied. Such complications can be avoided, in the vast majority of cases, by correctly indicating the surgery and by respecting the technical principles that guide it, also associated with specific care, which must be taken both pre-, inter- and post-operatively, both by the doctor and by the multidisciplinary team that is generally monitoring the patient (YACOUB; BAROUDI; YACOUB, 2012).

According to reports from three of the interviewees, the aesthetic procedures were carried out by nurses from the medical team that performed the abdominoplasty surgery, and the other five carried out the aesthetic procedures with a professional beautician. They all stated that aesthetic procedures were essential for reestablishing their daily routine. New treatment protocols have been used in an attempt to reduce the complications mentioned above. Among the resources used in these protocols, we can mention manual resources (manual lymphatic drainage - MLD and manual massage), kinesiotherapy, ultrasound, therapeutic laser, electrotherapy such as: transcutaneous electrical nerve stimulation (TENS), radiofrequency, vacuotherapy, cryotherapy, phototherapy, thermotherapy, the use of LEDs, among others (LEAL; SARA, 2017; BORGES; SCORZA; JAHARA, 2010).

According to De Godoy and Godoy (2020), manual lymphatic drainage is one of the main pillars of lymphedema treatment and contributes to transforming the clinical approach into the main form of treatment. Ultrasound (US) at a frequency of 3MHz is widely used in the inflammatory phase, it acts to stimulate tissue repair and its beneficial effect has been demonstrated on several tissues, highlighting the increase in angiogenesis, granulation tissue, the number of fibroblasts and collagen synthesis, in addition to the decrease in leukocytes and macrophages.

There is evidence demonstrating the effectiveness of US in the different phases of repair. Its use in the PO of plastic surgery helps in the reabsorption of hematomas, reducing the chances of fibrotic formation, preventing the formation of hypertrophic scars and keloids, and

it also improves cellular nutrition, reducing edema and pain, consequences of improved blood and lymphatic circulation (SANTOS; CÂNDIDO; SILVA, 2013; FONSECA, 2018).

US provides, through its thermal and non-thermal effects, an increase in the speed of tissue repair and healing of injuries, increased blood flow, increased tissue extensibility, dissolution of calcium deposits and reduced pain, through alteration of the nerve conduction and changes in cell membrane permeability. In addition to the benefits already mentioned, the reabsorption of hematomas stimulated by US is essential in the first phase of PO treatment, preventing fibrosis from occurring as a result (SANTOS; CÂNDIDO; SILVA, 2013; FONSECA, 2018). In general, seven patients stated that they were satisfied with the final result of the abdominoplasty.

#### 4.2 REFLECTIONS ON THE PERFORMANCE OF THE BEAUTIFULIST IN THE PRE- AND POST-OPERATIVE OPERATION.

Functional aesthetics is based on a solid scientific basis and is a strong contributor both pre- and post-operatively, preventing or treating responses arising from surgical interventions, also enabling the reduction of post-operative anxiety and despite its role beginning pre-operatively. operatively, his role becomes fundamental in the post-surgical period. Since the beautician can evaluate and choose the methods that can assist the pre- and post-operative treatment of plastic surgery, it will be possible to understand the entire process of interaction between the beautician and the plastic surgeon, aiming to minimize complications and contribute to a good postoperative evolution (LEAL; SARA, 2017; BORGES; SCORZA; JAHARA, 2010).

Although it may seem unnecessary to some surgeons, aesthetic care before plastic surgery is extremely important in the rehabilitation of the operated patient. The presence of postoperative fibrosis from previous surgeries can also interfere with the outcome of the surgery and should preferably be treated preoperatively. The presence of circulatory changes such as edema, lymphedema and fibrous edema geloid must be identified pre-operatively to make the patient aware that not all aesthetic conditions will be treated with surgery and that additional pre- and post-operative treatment will be necessary. (LEAL; SARA, 2017; BORGES; SCORZA; JAHARA, 2010). The preoperative period also serves as guidance for the patient. It's time to prepare for the

surgery, and where its limitations are known and the post-surgical treatment plan begins (LEAL; SARA, 2017; BORGES; SCORZA; JAHARA, 2010). The role of the beautician begins pre-operatively, aiming for a faster, more efficient and functional surgical recovery (DE MACEDO; DE OLIVEIRA, 2010). Aesthetics plays an important role in abdominoplasties. During the preoperative phase, we begin lymphatic drainage work, with the aim of preventing episodes of complex lymphedema in the postoperative period, common especially in total abdominal dermolipectomies.

The manipulation of connective tissue is of great importance, promoting mobility to the skin in its deepest planes and facilitating its detachment during the surgical procedure. The periumbilical region also deserves to be manipulated to activate and increase peripheral circulation, with the aim of preventing possible fibrosis (LEAL; SARA, 2017; BORGES; SCORZA; JAHARA, 2010).

It should be noted that the beautician will work, pre-operatively, to prevent the formation of adhesions, the main aggravating factor in the post-operative period, as these adhesions impede the normal flow of blood and lymph, further increasing the edematous condition, delaying recovery. Post-operatively, it is extremely important for the patient to be referred to treatment in the immediate phase. The beautician's training allows him to identify the type and depth of the tissues involved, determine the stage of healing and recognize contraindications to the use of treatment modalities. Furthermore, he will be able to prioritize problems, establish goals and plan treatment in order to achieve the best possible result BORGES; SCORZA; JAHARA (2010).

It appears that more and more beauticians are setting up their own teams or being part of teams led by doctors. Aesthetics is increasingly in evidence in society, every day new specialization and professional development courses appear on the professional training market in this area, preparing professionals to work at the three levels of health care, through preventive and restorative measures and rehabilitative and provide academic training with a multi-professional vision (DE ARAÚJO; CABRAL, 2011).

There is a basis in the scientific literature to justify the choice of the different resources used in pathologies encompassed by aesthetics. On the other hand, research reports that many patients undergoing plastic surgery are not referred to pre- and

post-operative care with the physiotherapist or are referred at very late stages, which can lead to unsatisfactory results (DE MACEDO; DE OLIVEIRA, 2010).

## FINAL CONSIDERATIONS

When choosing to undergo plastic surgery, the person must be aware of the care that must be taken post-operatively and possible complications that may occur during this period. All physical, mental and emotional preparation is necessary. It is clear that the rehabilitative paradigm also applies to patients who undergo abdominoplasty. However, if care is available during the pre-operative period, it is possible to inform, prevent and guide the patient as well as their family members about the essential care in the immediate post-operative period, such as care with the incision, importance of rest and clarification of possible doubts that the patient may have at that moment.

Since the beautician can evaluate and choose methods that can assist in the pre- and post-operative treatment of abdominoplasty, it will be possible to understand the entire process of interaction between beauticians and plastic surgeons, aiming to minimize complications and contribute to a good evolution. postoperative. The role of the beautician begins preoperatively, aiming for a faster, more efficient and functional surgical recovery. Currently, there is an increase in plastic surgeries in the country and the decision to undergo such a procedure makes it necessary to clarify in advance the techniques adopted and possible postoperative complications. The beautician plays an important role in the pre- and post-operative treatment of abdominoplasty, preventing and/or minimizing common complications of this surgery. For the treatment to be effective, the beautician must know and understand the healing phases and their clinical characteristics.

Based on the study carried out, there are several aesthetic resources that can be used in the treatment, but lymphatic drainage was the most cited. It is necessary to carry out new studies on the subject and, as a suggestion for new research, longitudinal research is suggested, comparing the results in the short, medium and long term of people who underwent this surgery and used lymphatic drainage throughout of the postoperative period.

## REFERENCES

- ANGELIM, D. **Radiofrequency x Fibrosis**. Beauty Newsletter, June. 2010.
- BARROS, CJP **NMR-based metabonomics as a tool for discrimination of irradiated soybeans & diagnosis of hepatitis and liver fibrosis**. 2017.
- BORGES, F. dos S.; SCORZA, FA; JAHARA, RS **Therapeutic modalities for aesthetic dysfunctions**. 2010.
- BRAVO, BSF *et. al.* Treatment of gynoid lipodystrophy with unipolar radiofrequency: clinical, laboratory and ultrasound evaluation. **Surgical & Cosmetic Dermatology**, v. 5, no. 2, p. 138-144, 2013.
- CHI, A. *et. al.* The use of lymphotaping, combined therapy and manual lymphatic drainage on fibrosis in the postoperative period of abdominal plastic surgery. **Physiotherapy Brazil**, v. 17, no. 3, p. 197-203, 2016.
- DA SILVA, RMV *et. al.* **Assessment of scar fibrosis after liposuction and/or abdominoplasty**. CATUSSABA-ISSN 2237-3608, v. 3, no. 2, p. 19-28, 2014.
- DE ARAÚJO, APS; CABRAL, ML **Dermato-functional physiotherapy: a profile of postgraduate courses in the state of paraná**. 2011.
- DE GODOY, JMP; GODOY, M. de FG **Manual lymphatic drainage: new concept**. **Brazilian Vascular Journal**, v. 3, no. 1, p. 77-80, 2020.
- DE MACEDO, ACB; DE OLIVEIRA, SM **The role of physiotherapy in the pre- and post-operative period of body plastic surgery: a literature review**. **School of Health notebooks**, v. 2, no. 4, 2010.
- DETERLING, L.C. *et. al.* **Benefits of low-power laser in the post-surgical period of plastic surgery**. **Augustus Magazine**, v. 14, no. 29, p. 45-53, 2010.
- DI MARTINO, M. *et. al.* **Seroma in lipoabdominoplasty and abdominoplasty: comparative ultrasound study**. **Brazilian Journal of Plastic Surgery**, v. 25, no. 4, p. 679- 687, 2010.
- ESPER, L.R. **Comparative analysis of the effect of laser or low-power LED therapy during orthodontic movement - Clinical study** [Master's Thesis in Biomedical Engineering]. São José dos Campos, SP: Universidade Do Valle Do Paraíba, Institute of Research and Development; 2010.

FONSECA, R P. *et. al.* Influence of the physiotherapeutic approach in the postoperative period of abdominoplasty: A scientific approach. **Tiradentes University Research Week-SEMPEsq**, n. 19, 2018.

LANGE, A. **Manual lymphatic drainage in the postoperative period of plastic surgery**. Curitiba-PR: Vitoria graphic and publisher, 2012.

LEAL, S. **The role of dermatofunctional physiotherapy in abdominoplasty complications**. 2017.

MAUAD, R. **Aesthetics and plastic surgery**: pre- and post-operative treatment. São Paulo: Editora SENAC, 2011.

MIGOTTO, JS Functional dermatological physiotherapeutic performance in the postoperative period of plastic surgery. **Management and Health**, v. 4, no. 1, p. 1365-1377, 2012.

MURSHID, M. *et. al.* Abdominoplasty in obese and in morbidly obese patients. **Journal of plastic, reconstructive & aesthetic surgery**, v. 63, no. 5, p. 820-825, 2010.

NEAMAN, K.C. *et. al.* **Outcomes of traditional cosmetic abdominoplasty in a community setting**: a retrospective analysis of 1008 patients. *Plastic and reconstructive surgery*, v. 131, no. 3, p. 403e-410e, 2013.

RAMOS, RFM *et. al.* **Comparison between the application and non-application of LED (Light Emitted Diode) in the healing of patients undergoing abdominoplasty**. 2017.

ROBERTSON, V. **Electrotherapy explained**: principles and practice. Elsevier Brazil, 2011.

SAMRA, S. *et. al.* **Complication rates of lipoabdominoplasty versus traditional abdominoplasty in high-risk patients**. *Plastic and reconstructive surgery*, v. 125, n. 2, p. 683-690, 2010.

SANTOS, Lorryne Pereira; CÂNDIDO, CPR; SILVA, G. Dermatofunctional physiotherapy in the postoperative period of abdominoplasty: literature review. **Amazonia Science & Health Magazine**, P. 05-07, 2013.

SOARES, LMA; SOARES, SMB; SOARES, AK Comparative study of the effectiveness of manual and mechanical lymphatic drainage in the postoperative period of dermolipectomy. **Brazilian magazine on health promotion**, v. 18, no. 4, p. 199-204, 2012.

SOUZA, LS de; HARADA, MN; BOLOGNANI, EMC Comparison of the occurrence of seroma between conventional and anchor abdominoplasty techniques in post-bariatric patients. **Rev Bras Cir Plást**, v. 32, no. 1, p. 78-86, 2017.

VIEIRA, TS; NETZ, DJ **The formation of scar fibrosis after aesthetic surgery and its possible treatments**: review article. Balneário Camboriu: Universidade do Vale do Itajai, 2012.

YACOUB, CD; BAROUDI, R.; YACOUB, MB **Extended reverse abdominoplasty.**  
Brazilian Journal of Plastic Surgery, v. 27, no. 2, p. 328-332, 2012.

ZANELLA, BI; RUCKL, S.; VOLOSZIN, M. The importance of manual lymphatic drainage in the postoperative period of abdominoplasty. **Rev. Lit.**[periodical on the internet], 2011.

## APPENDIX A - INTERVIEW SCHEDULE

All questions below refer to pre- and post-abdominoplasty surgery.

1.Name:

2.Age:

3.Ethnicity: White, brown, yellow or black

4.Do you smoke: Yes or No

5.Do you drink alcohol? How often?

6.Do you drink alcohol? How often?

7. Do you practice physical activities? Which? And how often?

8. How long ago did you have your abdominoplasty?

9. Have you had any other procedures associated with abdominoplasty? Which?

10.What are the medical recommendations before performing an abdominoplasty?

11.After surgery, what medical recommendations and medications were used?

12. Did the doctor recommend any aesthetic procedure such as lymphatic drainage after surgery?

What others?

13.How many sessions have you had of Lymphatic Drainage? How many times a week?

14. When performing aesthetic procedures, did you use any device (ultrasound, radiofrequency, etc.) during the treatment? Which?

15.Which professional provided this pre- and post-operative care?

16. Do you believe that the professional's actions, pre- and post-operatively, were essential for reestablishing your daily routine?

17. Were there any postoperative complications?

18. Were you satisfied with the result of the surgery?