

## FELINE SPOROTRICHOSIS: CASE REPORT FELINE SPOROTRICHOSIS: CASE REPORT

Mariana Silvestre de Oliveira Donatilio - Undergraduate in Veterinary Medicine at Serra Dourada College - marianadonatilio@gmail.com

Marcia Cristina Pires Ferrão - Veterinary doctor graduated from UNINASSAU - marciadois@gmail.com

Isadora Aparecida Reis Barbosa - Undergraduate in Veterinary Medicine at the Federal University of Lavras - Isadora.barbosa@estudante.ufla.br

Carlos Henrique da Silva Xavier - Graduating in Veterinary Medicine from Santa Úrsula University - carlos99hxavier@gmail.com

Aline dos Santos Barbosa - Undergraduate in Veterinary Medicine at the University Center of the Americas (FAM) - line67184@gmail.com

Rodrigo de Souza Borges - Undergraduate in Veterinary Medicine at the University Center of the Americas (FAM) - rodrigoborgesb@gmail.com

**SUMMARY:**In the clinical practice of small animals, cases of sporotrichosis in felines are recurrent. This disease, considered an endemic zoonosis since the 1990s, has cats as its main transmitters. Due to the behavioral nature of felines, especially those with escape and aggressive habits, the spread of sporotrichosis is favored, making its epidemiological control a significant challenge. The objective of this study is to present a clinical case of sporotrichosis in a feline, contextualized by a literature review on the pathology. The case report will detail the diagnosis, treatment, and management of the affected animal. It is concluded, based on the literature and clinical experience, that prolonged use of itraconazole is essential for successful treatment, as well as the need for containment measures, such as preventing escapes, to prevent the spread of the disease.

**Keywords:***Sporothrix schenckii*.Dermatology. Small animals.

1

**ABSTRACT:**In the clinical practice of small animals, cases of sporotrichosis in felines are recurrent. This disease, considered an endemic zoonosis since the 1990s, has cats as its main transmitters. Due to the behavioral nature of felines, especially those with escape and aggressive habits, the spread of sporotrichosis is favored, making its epidemiological control a significant

challenge. The objective of this study is to present a clinical case of sporotrichosis in a feline, contextualized by a literature review on the pathology. The case report will detail the diagnosis, treatment, and management of the affected animal. It is concluded, based on the literature and clinical experience, that prolonged use of itraconazole is essential for successful treatment, as well as the need for containment measures, such as preventing escapes, to prevent the spread of the disease.

**Keywords:** *Sporothrix schenckii*. Dermatology. Small animals.

## 1. INTRODUCTION

Caused by fungus *Sporothrix schenckii*, is a subcutaneous mycosis that mainly affects felines, dogs and humans. In cats, infection occurs predominantly through scratches, bites or direct contact with secretions from contaminated lesions. This zoonosis, in addition to presenting a high risk to public health, is an easily spread disease, especially in urban environments with a high density of stray animals and a lack of population control (REZNIK, 2022; ARAÚJO et al., 2020).

In the clinical routine of small animals, it is very common to find cases of sporotrichosis in felines. This pathology was considered an endemic zoonosis in the 1990s, with felines as the main transmitter. It still has high relevance for epidemiological control, as animals that maintain escape habits and high aggressiveness can facilitate dissemination (ASSIS et al., 2022; MINISTRY OF HEALTH, 2023).

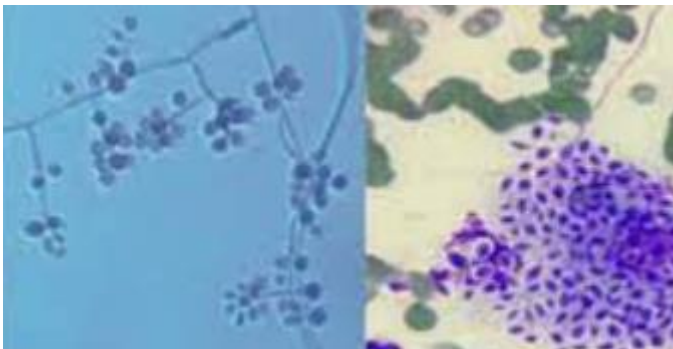
The primary objective of this research is to address a clinical case of a feline with sporotrichosis. In addition, the specific objectives are: to address the main characteristics of sporotrichosis in felines; to describe the treatment of choice for the pathology; to unravel the main aspects of the epidemiology of sporotrichosis.

## 2 THEORETICAL FRAMEWORK

### 2.1 EPIDEMIOLOGY OF SPOROTRICHOSIS

Sporotrichosis is a zoonosis frequently responsible for epidemic outbreaks in several regions of Brazil. It is an infectious disease, present mainly in domestic felines, caused by dimorphic and saprophytic fungi of the genus *Sporothrix spp.*, with serious impacts on public health (ASSIS et al., 2022). This genus of fungi belongs to the Ascomycota division, Euascomycetes subclass, Ophiostomatales order and Ophiostomataceae family (REZNIK, 2022). Figure 1 illustrates the *Sporothrix spp.*

**Figure 1** *Sporothrix spp.*



Source: Ministry of Health, 2019

To better understand this fungus, it is essential to analyze its epidemiology, highlighting its hosts. Although cats are the main host, sporotrichosis can affect humans, dogs, and other animals (MACHADO et al., 2019). The infected cat is considered the main source of infection, transmitted by direct contact, through scratches and oronasal secretions. The entry points for the fungus into the body are the mucous membranes, damaged epithelial tissues, and, rarely, the respiratory tract (ASSIS et al., 2022; MINISTRY OF HEALTH, 2023). In the environment, the fungus can be found in places with a large amount of organic matter or decaying vegetation. For this reason, sporotrichosis was long known as "gardener's disease", being considered an ergodermatosis (ARAÚJO et al., 2020).

The incubation period of the disease varies and can last days, weeks or even months. In cats, clinical manifestations include wounds on the face and paws, lack of appetite, weight loss, nasal secretions and sneezing. In humans, reddish nodules appear that evolve into wounds, usually located on the arms, hands and feet, and can also cause pain and fever (MINISTRY OF HEALTH, 2019).

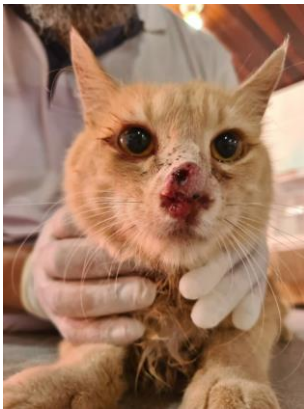In humans, sporotrichosis can present in four main forms: cutaneous sporotrichosis, lymphocutaneous sporotrichosis, extracutaneous sporotrichosis and disseminated sporotrichosis. The diagnosis must be made under medical supervision, based on complementary exams such as cytology, mycological culture, intradermal reaction and histopathological exams, in addition to the evaluation of the patient's clinical history (ARAÚJO et al., 2020).

## 2.2 RELEVANT CHARACTERISTICS OF FELINE SPOROTRICHOSIS

In felines, sporotrichosis presents very evident clinical signs such as skin ulcerations originating from nodules, very common on the head, paws and tail, where they can secrete purulent mucus, indicating high inflammation at the sites of the lesions (GUIMARÃES; GUIMARÃES, 2022).

This pathology can manifest itself in different ways, such as: fixed cutaneous, lymphocutaneous, disseminated cutaneous, extracutaneous and systemic. In domestic cats, the cutaneous forms are more common: fixed and disseminated with the presence of purulent and crusted lesions, which can evolve into a necrosis process if not treated properly, having greater incidence in the facial region of animals, mainly affecting the nasal region - Figure 2 (GUIMARÃES; GUIMARÃES, 2022; SANTOS et al, 2022).

**Figure 2** Skin lesion in the nasal region of a feline



Source: Barros, 2023

The treatment is long, lasting from 2 to 6 months, using antifungals such as itraconazole (the drug of choice), fluconazole, terbinafine and ketoconazole. The recommended dose of itraconazole is 50-100mg per animal, SID, after the disappearance of clinical signs, treatment should continue for another 30 days. In addition, maintaining daily cleaning of the wounds is necessary (SANTOS et al, 2022; BEDRIKOW; NOVAIS-MENCALHA, 2022).

In most cases, the diagnosis is made based on the signs presented, such as lesions on the face. However, laboratory tests should not be dispensed with, and cytopathology, histopathology and mycological culture may be chosen, the latter being considered the gold standard for the disease (REZNIK, 2023).

The prognosis in more severe cases is considered reserved, as the infection in the lesions is disseminated and, as it is a long treatment, the animal may not survive until the end of it. However, it is important to highlight that feline sporotrichosis is curable, even though it has a complicated treatment (BEDRIKOW; NOVAIS-MENCALHA, 2022).

## 2. MATERIAL AND METHOD

This research adopts a qualitative approach, based on a systematic and concise literature review. Data collection was carried out predominantly in the Google Scholar database, prioritizing studies published in the last 5 years as inclusion criteria, in order to guarantee the relevance and timeliness of the information. The following were selected:

articles that present a significant contribution to the understanding of the proposed theme, considering the practical applicability of the findings in clinical conduct.

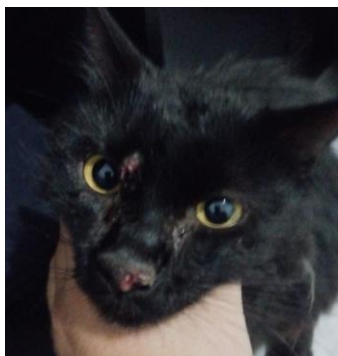
In addition to the literature review, a case report of a feline, mixed-breed, approximately 3 years old, will be presented. In this report, the clinical characteristics, diagnosis, and therapeutic approaches adopted will be discussed, providing a detailed analysis of the clinical interventions performed in the management of the patient.

### 3. RESULTS AND DISCUSSION

The case in question involves a male, neutered feline, approximately 3 years old, unvaccinated and unwormed. The main complaint reported was the appearance of several lesions on the animal's face and a comprehensive lesion on the right front paw (Figures 3 and 4).

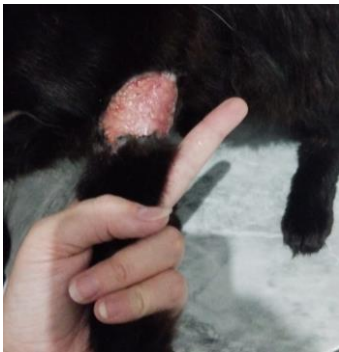Initially, the diagnosis of sporotrichosis was inferred based on the signs presented, such as those described by Guimarães and Guimarães (2022). In addition, it was alleged by the owner that the injury to the right forelimb (MAD) occurred after the animal “walked” on the street, returning home with a bite-like injury, which was not treated properly and spread.

**Figure 3** Facial injuries



Source: Own authorship

**Figure 4**MAD injury



Source: Own authorship

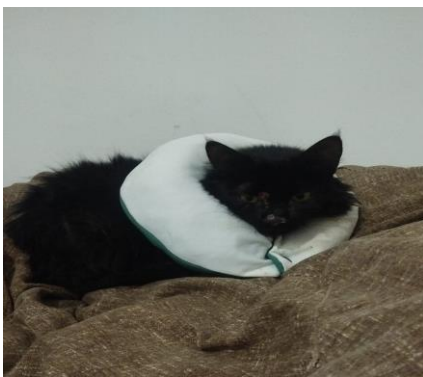After assessing vital parameters, including heart rate, respiratory rate, temperature and dehydration level, it was found that all were within normal limits. Although no additional tests were performed during the first consultation, the guardian was reminded of the importance of performing them. As stated by Reznik (2020) in his research, additional tests are essential throughout the treatment. However, in the case in question, the guardian chose not to authorize more detailed analyses at the beginning of the follow-up.

Therefore, itraconazole 100 mg was prescribed, administered once a day (SID) for 60 days, and meloxicam at a dose of 0.5 mg SID for 5 days. The use of an Elizabethan collar was also recommended. In the office, trichotomy was performed around the lesions located in the abdominal and caudal region, and the use of Kuramed® was prescribed after cleaning with saline solution, to be applied SID until the lesions were completely closed. As described by Bedrikow and Novais-Mencalha (2022), who carried out a study on the case series of the antifungal agent used in this case, itraconazole demonstrated greater efficacy compared to other antifungal agents.

After a few weeks, partial healing of the lesions was observed, and the owner reported that the use of the Elizabethan collar was interfering with the animal's feeding. In view of this, it was recommended to make an adapted cushion for greater comfort (Figure 5). Additionally, the importance of thoroughly cleaning the environment with water and sodium hypochlorite (NaClO) once a day was reinforced, in addition to the use of gloves when handling the animal. As mentioned by Machado et al. (2019), the use of Personal Protective Equipment (PPE) during handling is also recommended to ensure safety.

Near the end of the 60-day treatment, the owner returned with the animal reporting respiratory difficulties. During the evaluation, an intranasal mass was identified that compromised the animal's breathing. Therefore, a cytopathological examination was performed to rule out the possibility of neoplastic alterations, such as nasal adenocarcinoma, in addition to a rapid test for FIV/FelV. The results indicated only inflammatory activity, and the rapid test was negative for both diseases (Figures 6 and 7).

### Figure 5 Adapted pillow



Source: Own authorship

### Figure 6 Cytopathological examination result

#### Citopatológico

##### ANÁLISE MICROSCÓPICA

Coloração da (s) lâmina (s) citológica (s) em Panótico rápido

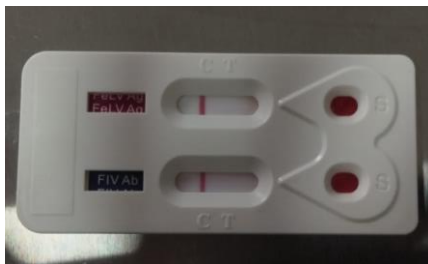
A análise microscópica das lâminas citológicas revela celularidade alta, representada por neutrófilos íntegros e necróticos. Raros plasmócitos, linfócitos e macrófagos. Ocasionais queratinócitos típicos. Raros restos celulares. Não há indícios de malignidade ou agentes infecciosos.

##### CONCLUSÃO

Achados citopatológicos favorecem o diagnóstico de inflamação aguda neutrofilica.

Source: Own authorship

**Figure 7** FIV/FeLV Test



Source: Own authorship

Upon return, the use of itraconazole SID was prescribed for another 60 days, in addition to meloxicam 0.5 mg SID for 5 days. After one week, the owner reported a reduction in the intranasal mass, and the treatment was successful in remitting the lesions. Currently, the feline is in good health. According to the guidelines of the Ministry of Health information (2019; 2023), the owner was emphasized the importance of installing gates in the residence to prevent the animal from escaping, as well as the relevance of vaccination to ensure its health.

When analyzing the therapeutic conduct instituted in the animal, it can be stated that it is in accordance with that described by Santos et al. (2022) and Barros (2023), who indicate itraconazole as the drug of choice, also highlighting the possible duration of treatment. In addition, Araújo et al. (2020) and Assis et al. (2022) reinforce that the disease can be transmitted through the environment, since the responsible fungus remains viable in contaminated places, making constant hygiene essential to prevent new infections. Thus, the treatment adopted and the guidelines provided to the guardian followed current scientific recommendations.

## FINAL CONSIDERATIONS

Considering the above, it is possible to note the relevance of the use of itraconazole in the treatment of sporotrichosis, being considered by the cited authors as the drug of choice for the disease. In addition, the control of escapes and risky behaviors, such as fights with other animals, is essential to prevent the spread of the zoonosis, reinforcing the need for adequate management of infected felines. These measures are essential both for the recovery of the animal and for reducing the transmission of the disease to other animals and humans.

The importance of this case report lies in the opportunity to illustrate the practical application of the therapeutic and management guidelines for sporotrichosis in a real clinical context. By documenting

By detailing the diagnosis, treatment with itraconazole and the control measures adopted, this case contributes to a deeper understanding of the pathology and to the application of effective practices in the management of the disease. In addition, it provides a valuable example of how the combination of pharmacological therapies with behavioral control strategies can improve clinical outcomes and reduce the spread of the disease, serving as a reference for professionals in the field and helping to improve therapeutic and prevention approaches in future cases.

## REFERENCES

ARAÚJO, Adjanna Karla Leite; GONDIM, Adriana Leão de Carvalho Lima; ARAÚJO, Igor Emanuel Alcântara de. Feline and human sporotrichosis – report of a zoonotic case. **Brazilian Journal of Animal Hygiene and Health**, Fortaleza, v. 14, n. 2, p. 237-247, Apr./Jun. 2020. Available at: <https://repositorio.ufc.br/handle/riufc/53866>. Accessed on: Sep. 16, 2024.

ASSIS, Gabriela Silva et al. Feline sporotrichosis and public health. **Veterinary and Animal Science**, v. 29, p. 1- 10, 2022. Available at: <https://rvz.emnuvens.com.br/rvz/article/view/594>. Accessed on: June 25, 2024.

BARROS, Alcindo. Research at Uema studies Sporotrichosis in Cats. **State University of Maranhão**. 2023. Available at: <https://www.uema.br/2023/12/pesquisa-na-uema-estuda-aesporotricose-em-gatos/>. Accessed on: September 15, 2024.

BEDRIKOW, Sofia Luyten; NOVAIS-MENCALHA, Renata Novais-Mencalha. Feline sporotrichosis responsive to itraconazole treatment in São Paulo: Case report. **Pubvet**, v. 16, n. 11, 2022. Available at: <https://www.pubvet.com.br/uploads/929c982bf8ba4776178855f945498efe.pdf>. Accessed on: September 16, 2024.

GUIMARÃES, Ticiania Machado; GUIMARÃES, André Barreto. Feline sporotrichosis: Case reports. **Pubvet**, v. 16, n. 1, p. e1005, 2022. Available at: [https://web.archive.org/web/20220209173755id\\_/http://www.pubvet.com.br/uploads/89c16e176dadecca065eab84ce642604.pdf](https://web.archive.org/web/20220209173755id_/http://www.pubvet.com.br/uploads/89c16e176dadecca065eab84ce642604.pdf). Accessed on: August 23, 2024.

Machado, B. A., et al. (2019). **Understanding sporotrichosis**: Everything you need to know about the disease. Available at: <https://vet.ufmg.br/wp-content/uploads/2023/03/Cartilha-Esporotricose-Versao-Digital.pdf>. Accessed on: April 22, 2024

MINISTRY OF HEALTH (BR). (2023). **Sporotrichosis**: What do you, as a healthcare professional, need to know about it? Available at: <https://www.gov.br/saude/pt-br/assuntos/saude-de-a-az/e/esporotricose-humana/arquivos/folder-esporotricose-para-profissionais-de-saude>. Accessed on: April 22, 2024.

MINISTRY OF HEALTH (BR). (2019). **What might you and your cat have in common?** A disease that puts your health and that of your cat at risk! [FOLDER]. Available at: <https://www.gov.br/saude/pt-br/assuntos/saude-de-aaz/e/esporotricose-humana/arquivos/folderesporotricose-para-populacao-geral>. Accessed on: April 22, 2024.

REZNIK, AU (2022). Feline sporotrichosis. Final Course Work [Graduation in veterinary medicine] - **Faculty of Veterinary Medicine and Animal Science of the University “Júlio de Mesquita Filho”**, Botucatu Campus, SP, to obtain the degree of veterinarian. Available at: <https://repositorio.unesp.br/server/api/core/bitstreams/6d99b485-0e4e-4262-9636-e7d81225ca2f/content>. Accessed on: August 8, 2024.

SANTOS, Alessia Nunes et al. Sporotrichosis in felines: Review. **Pubvet**, v. 16, p. 195, 2022. Available in: [https://web.archive.org/web/20220818011246id\\_/http://www.pubvet.com.br/uploads/37becf27b65871af4c37077d0f040e50.pdf](https://web.archive.org/web/20220818011246id_/http://www.pubvet.com.br/uploads/37becf27b65871af4c37077d0f040e50.pdf). Accessed on: August 25, 2024.