

GENERAL ASPECTS,
TECHNIQUES OF
APPLICATION AND
EFFECTS
COLLATERALS OF
USE OF ACID
HYALURONIC NA
BIOMEDICINE
AESTHETICS

GENERAL
ASPECTS,
APPLICATION
TECHNIQUES AND
SIDE EFFECTS OF
THE USE OF
HYALURONIC ACID
IN AESTHETIC
BIOMEDICINE

SOUZA, Wanessa De Oliveira [1]

[1] Master's student in health sciences, graduating in biomedicine from Faculdade Joaquim Nabuc (UNINABUCO), graduated in Aesthetics from Fundação Mineira de Educação e Cultura (FUMEC), Postgraduate in advanced aesthetics distance education from Uniasselvi Postgraduated in acupuncture from Faculdade da Serran Region (FARESE).
wanessadeoliveirasouza@gmail.com

SUMMARY

This study describes and analyzes the general aspects, application techniques and side effects of the use of hyaluronic acid in aesthetic biomedicine. Taking into account that aesthetics is actually one of the most powerful segments of the economy, there is a huge demand for aesthetic procedures to alleviate body and facial disorders. Contemporary society is increasingly concerned with maintaining a youthful and harmonious appearance, leading to a constant search for methods that soften or delay the expression of these signs, thus maintaining a youthful skin appearance for longer. Currently, the use of fillers in aesthetics has expanded considerably. Becoming a tool more and more, but used to aid rejuvenation. There are currently numerous different types of fillers, however there is no ideal, pure filler on the market without adverse effects. Among fillers, hyaluronic acid (HA) is the one that comes closest to these expected peculiarities, which is why it is the one that has been most used, however, it should be noted that it can present some adverse effects. The present study aimed to describe and analyze the general aspects and application techniques of hyaluronic acid in aesthetic biomedicine, expose its risks and enumerate its possible complications. To this end, a bibliographical search was carried out in the main databases, the virtual health library (bvs); scientific electronic library online (scielo), Google scholar and lilacs. Concluding, then, that HA is an effective and relatively safe alternative for various uses in aesthetic biomedicine.

Key words: Fillers. Aging Facial. Hyaluronic acid. Aesthetic biomedicine.

ABSTRACT

This study describes and analyzes the general aspects, application techniques and side effects of the use of hyaluronic acid in aesthetic biomedicine. Taking into

account that aesthetics is factually one of the most powerful segments of the economy, there is a huge demand for aesthetic procedures to alleviate body and facial disorders. Contemporary society is increasingly concerned with maintaining a youthful and harmonious appearance, leading to the constant search for methods that soothe or delay the expression of these signs, thus remaining with the appearance of young skin for a longer time. Currently, the use of fillers in aesthetics has expanded considerably. Becoming a tool every time, but used to aid rejuvenation. There are currently many different types of fillers, however there is no ideal, pure filler on the market without adverse effects. Among the fillers, hyaluronic acid (HA) is the closest to these expected peculiarities, for this reason it is the one that has been most used, however it is emphasized that it can have some adverse effects. The present study aimed to describe and analyze the general aspects and techniques of application of hyaluronic acid in aesthetic biomedicine, expose its risks and list its possible complications. To this end, a bibliographic search was carried out in the main databases, the virtual health library (bvs); scientific electronic library online (scielo), academic Google and lilacs. Concluding then that HA is an effective and relatively safe alternative for several uses in aesthetic biomedicine. **Keywords:** Fillers. Facial aging. Hyaluronic acid. Aesthetic biomedicine.

1. INTRODUCTION

Aesthetics is actually one of the most powerful segments of the economy, Brazil is the third largest consumer of beauty products and aesthetic services in the world, due to the enormous demand for aesthetic procedures to alleviate body and facial disorders. Contemporary society is increasingly concerned with maintaining a young and harmonious appearance, as through the appearance of the skin it is possible to observe the advancement of age, leading to the search for resources that can alleviate these effects, thus encouraging the aesthetics market to evolve its protocols, products and services, due to this growing demand, there is a need for a constant evolution of therapies available in aesthetics, thus boosting scientific research in the area of aesthetic biomedicine (DA ROCHA BRITO; FERREIRA, 2018; SANTONI, 2018; FERREIRA; CAPOBIANCO, 2016).

The skin is the largest organ of the human body, it forms a semi-permeable barrier that provides protection and regulation between the internal and external environments of the human body, it determines appearance, racial and sexual characteristics (SANTONI, 2018; PEREIRA; DELAY, 2017). Hyaluronic acid is naturally present in the extracellular matrix of connective tissues, synovial fluid, intraocular fluid and the vitreous body of the eye, in addition to the epithelial tissue, where it forms the elastic and viscous fluid matrix that surrounds collagen fibers, elastic fibers and intercellular structures. Its concentration in the skin reduces with

aging, resulting in a decrease in hydration, making the dermis less voluminous, forming the disorders that characterize skin aging. (DA ROCHA BRITO; FERREIRA, 2018; CROCCO; ALVES; ALESSI, 2012).

Over the years, the skin undergoes changes in its characteristics due to intrinsic and extrinsic factors, causing a reduction in the elasticity of the tissue and its adipose layer, atrophy, loss of collagen, among others, thus making the signs characteristic of skin aging. more visible, wrinkles, expression lines, reduced hydration and luminosity and increased sagging appear. For this reason, individuals are constantly searching for methods that alleviate or delay the expression of these signs, thus maintaining the appearance of youthful skin for longer (DA ROCHA BRITO; FERREIRA, 2018; CROCCO; ALVES; ALESSI, 2012; SANTONI, 2018).

Currently, the use of fillers in aesthetics has expanded considerably. Becoming a tool more and more, but used to aid rejuvenation. There are currently numerous different types of fillers, classified as temporary, semi-permanent (minimum stay in the tissue for 18 months) and permanent, and are also characterized according to their composition of collagen, hyaluronic acid, polylactic acid, polymethyl methacrylate and hydroxyapatite (CROCCO; ALVES; ALESSI, 2012; SANTONI, 2018). Fillers are indicated for the treatment of rhytids, repair of atrophic scars and small skin imperfections, in addition to improving the facial contour. They are expected to provide excellent aesthetic results, have a long duration, are stable and safe, with minimal complications (CROCCO; ALVES; ALESSI, 2012).

However, there is no ideal filler on the market, pure and without adverse effects. Among fillers, hyaluronic acid (HA) is the one that comes closest to these expected peculiarities, which is why it is the one that has been most used, however, it should be noted that it can present some adverse effects. It is a temporary resorbable filler from the glycosaminoglycan (GAG) family, with synthetic or animal origin, used to minimize damage to the skin due to its considerable hygroscopic activity, providing filling, volume, support, hydration and elasticity to the skin, thus delaying signs of aging (CROCCO; ALVES; ALESSI, 2012; SANTONI, 2018; GARBUGIO; FERRARI, 2010; SALLES *et al.*, 2011). Given this scenario and taking into account that hyaluronic acid currently has several applications both in aesthetics and in other areas.

areas, this article is expected to describe and analyze the general aspects and application techniques of hyaluronic acid in aesthetic biomedicine, expose its risks and enumerate its possible complications, thus, the research problem has as its guiding question: What are the aspects general information, application techniques and side effects of using hyaluronic acid in aesthetic biomedicine? To answer the guiding question presented in the research problem, this study aimed to describe the main characteristics, the application techniques of hyaluronic acid in aesthetic biomedicine, describe its risks and enumerate its possible complications.

This research is justified as it considers the appropriation of literature to be fundamental to advance knowledge regarding the various applications of hyaluronic acid in aesthetic biomedicine, its risks and possible side effects. After an analysis of the specialized literature, it was reflected that, however, there are not enough scientific studies that relate hyaluronic acid, its applications, risks and adverse effects in the area of aesthetic biomedicine, making it essential to carry out scientific research in this area.

2 THEORETICAL FOUNDATION

2.1 HUMAN INTEGUMENTARY SYSTEM

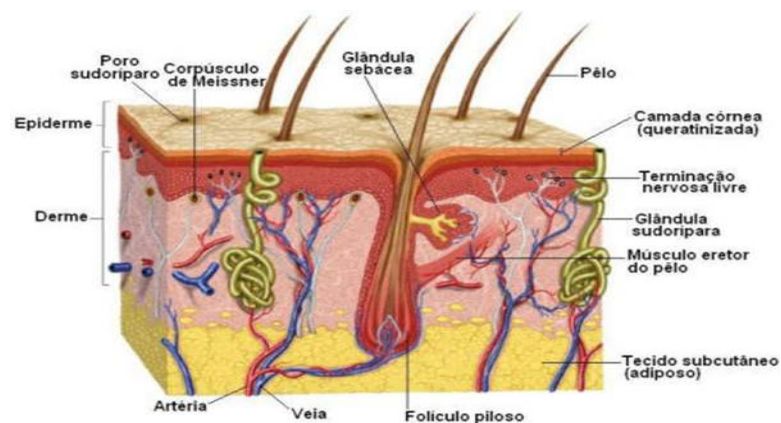
The skin is the largest organ in the human body, as it covers the entire body, weighing approximately 4.5 kg, that is, 15% of the human body volume. It has specialized, flexible, resistant and complex structures, being responsible for numerous extremely important functions, such as perspiration, perception, physical and immunological protection, pigmentation, nutrition, keratogenesis, defense, metabolism, absorption, secretion, excretion and thermoregulation, Therefore, the skin behaves as a thermal insulator, regulating water and electrolyte loss, thus conserving body temperature (NAYLOR; WHATSON; SHERRATT, 2011; DA ROCHA BRITO; FERREIRA, 2018; RUIVO, 2014; JUNQUEIRA; CARNEIRO, 2013; MONTANARI, 2016; ESMERALDO, 2014).

The skin acts as an enveloping and insulating membrane, a physical barrier against external aggressions, reducing the penetration of foreign, chemical and harmful substances,

protecting against the action of pathogenic microorganisms and ultra violet radiation, in addition to its capacity for tissue regeneration, a complex process that aims to restore the integrity of injured tissue. Sensory and autonomic nerves are a structural part of the skin, they are necessary for detecting touch, vibration, pressure, temperature, pain and itching, their biomechanical properties act in response to deformation force (NAYLOR; WHATSON; SHERRATT, 2011; DA ROCHA BRITO; FERREIRA, 2018; EMERALDO, 2014).

Three overlapping layers make up the skin. The epidermis is the most superficial layer, it is the main defense barrier, the intermediate layer is a very vascularized layer called the dermis and the deepest layer is the hypodermis, made up of adipose tissue. In figure 1 we have a graphic representation of the structures of the human integumentary system. They perform their functions autonomously, experiencing regulation, molecular and cellular modeling while performing their functions. Water makes up around 70% of the skin, distributed throughout the layers, with the hypodermis being the most hydrated, it also contains proteins, lipids, carbohydrates and mineral salts (NAYLOR; WHATSON; SHERRATT, 2011; DA ROCHA BRITO; FERREIRA, 2018; JUNQUEIRA ; CARNEIRO, 2013; MONTANARI, 2016;

Figure 1- Structures of the Human Integumentary System



Source: (Oliveira, 2011).

2.1.1 Epidermis, dermis and hypodermis

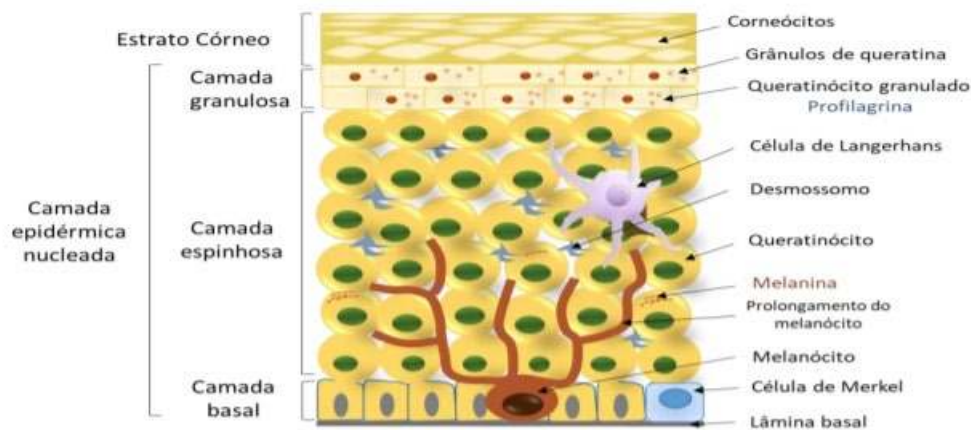
The epidermis is made up of stratified squamous epithelium that is continually renewed. The capillaries of the adjacent superficial dermis nourish the epidermis by diffusion as it is avascular. It is mainly composed of keratinocytes (>90%), these cells maintain homeostasis and the constant renewal of the hair follicles of the epidermis, this differentiation renews the epithelium throughout life through keratinization, the keratinocytes move progressively from the basement membrane to the surface of the skin, where they peel off, forming several distinct layers along this path, figure 2, they are: the basal or germinative stratum, the deepest layer, connected to the dermis by the hemidesmosomes that are attached to the basal membrane, this stratum is made up of a single layer of mostly keratinocytes, interspersed by Merkel cells and melanocytes, with melanocytes being responsible for the production of melanin that gives skin pigmentation (NAYLOR; WHATSON; SHERRATT, 2011; DA ROCHA BRITO; FERREIRA, 2018; JUNQUEIRA; CARNEIRO, 2013; MONTANARI, 2016;

The stratum spinosum or Malpighi is located on the stratum basale and consists of 8 to 10 layers of cells, contains desmosomes and Langerhans cells that participate in immune function. The stratum granulosum is made up of 2 to 5 layers of flattened cells with a granular structure due to the presence of keratohyaline grains that act as a barrier and participate in cohesion between cells due to their high amount of lipids, phospholipids and proteins. On the surface of this stratum, the nucleus and organelles of the cell disintegrate and the cell dies, forming the stratum corneum, the most superficial layer of the epidermis and contains several layers of dead squamous cells, united by desmosomes, called corneocytes, which are dead, anucleated keratinocytes. and keratinized, they are rich in keratin, lipids and water, forming an impermeable barrier (NAYLOR; WHATSON; SHERRATT, 2011; DA ROCHA BRITO; FERREIRA, 2018; JUNQUEIRA; CARNEIRO, 2013; MONTANARI, 2016; ESMERALDO, 2014).

The thickness of the stratum corneum can vary according to the region of the body, reaching 1.5 mm on the soles of the feet and palms of the hands, where it gains an additional palmoplantar layer, the stratum lucidum, this layer is composed of dead, homogeneous cells It is

translucent whose function is protection. Cell renewal lasts approximately 28 days, and may undergo changes caused by pathological processes (NAYLOR; WHATSON; SHERRATT, 2011; DA ROCHA BRITO; FERREIRA, 2018; JUNQUEIRA; CARNEIRO, 2013; MONTANARI, 2016; ESMERALDO, 2014).

Figure 2- Layers of the epidermis



Source: (SOUSA, 2018).

Composed of an amorphous fundamental substance, horny skin annexes and several cells, among them, we have fibroblasts, responsible for the synthesis of collagen and elastin, the dermis is located above the hypodermis and below the epidermis, joined to the epidermis by the dermoepidermal junction, a composite structure by fibroblasts, these form collagen and elastin that offer resistance against external forces that cause deformation, serving as an impermeable barrier, and signaling for tissue growth and regeneration. The dermis has variable thickness and great resistance against mechanical aggression. It contains vascular and nervous structures, sebaceous and sweat glands and hair follicles. Below the dermis, there is also the hypodermis, formed by fibrous, elastic and fatty tissues (NAYLOR; WHATSON; SHERRATT, 2011; DA ROCHA BRITO; FERREIRA, 2018; JUNQUEIRA; CARNEIRO, 2013; MONTANARI, 2016; ESMERALDO, 2014).

The dermis is segmented into superficial or papillary dermis, located at the dermoepidermal junction, is very vascularized, rich in fibers and nerve endings, enabling metabolic exchanges with the germ layer, has several cells and thin bundles

fibrillar; The deep or reticular dermis, located in the lower part of the dermis, is made up of large collagen bundles, and finally the adventitious dermis, made up of thin collagen bundles, distributed between the appendages and vessels. The hypodermis is the deepest layer of the skin located below the reticular dermis, relating in its upper portion to the deep dermis, constituting the dermo-hypodermic junction (NAYLOR; WHATSON; SHERRATT, 2011; DA ROCHA BRITO; FERREIRA, 2018; JUNQUEIRA; CARNEIRO, 2013;

The hypodermis has variable thickness and is made up exclusively of adipocytes, collagen and blood vessels, which are larger in caliber than those of the dermis. It behaves like a subcutaneous tissue, subcutaneous tissue or superficial fascia. It functions as an energy reservoir called adipose tissue, a thermal insulator that, in addition to cushioning the skin, allows its mobility over adjacent tissues. The distribution of adipose tissue is not uniform in all regions of the body, some regions may not accumulate fat, such as the eyelids, the umbilical scar, the sternum region, the penis, and the joint folds. In other regions, in contrast, there is greater accumulation of adipose tissue: the proximal portion of the limbs and the lateral portions of the abdominal wall (NAYLOR; WHATSON; SHERRATT, 2011; DA ROCHA BRITO; FERREIRA, 2018; JUNQUEIRA; CARNEIRO, 2013; MONTANARI, 2016; EMERALDO, 2014).

Collagen is the most abundant and functional protein present in the human body, it constitutes the extracellular framework in all living beings, offers resistance and structural integrity to various organs and tissues, it also acts in the healing process and/or tissue regeneration, in addition to helping in skin hydration. There are nineteen distinct classes of collagen, distributed between types I to XIX. Type I is the most abundant in the human body, it is the most important for tissue elasticity, while type IV integrates the dermoepidermal junction and basement membrane. Collagen represents 30% of the total dermis and 75% of this is formed by type I and type III collagen (NAYLOR; WHATSON; SHERRATT, 2011; DA ROCHA BRITO; FERREIRA, 2018; RUIVO, 2014; JUNQUEIRA; CARNEIRO, 2013; MONTANARI, 2016; EMERALDO, 2014).

Elastin is a fibrous protein with elastic resistance that allows the skin to recover its original shape after being pulled. These fibers are thin in the papillary dermis, allowing vertical branches in relation to the epidermis, and thick in orientation

horizontal in the reticular dermis. Elasticity is the skin's ability to return to its initial state, after the forces that cause this extension cease. This capacity depends on the activity of elastic and collagen fibers, and the hydration state of the fundamental substance, determining the importance of maintaining the skin's water content (NAYLOR; WHATSON; SHERRATT, 2011; DA ROCHA BRITO; FERREIRA, 2018; RUIVO, 2014 ; JUNQUEIRA; CARNEIRO, 2013; Considering that the skin is the receptor of various cosmetic substances, knowledge of its structures and physiology is considered fundamental, and it is also essential to learn the nuances of skin aging (DA ROCHA BRITO; FERREIRA, 2018; RUIVO , 2014; SANTONI, 2018).

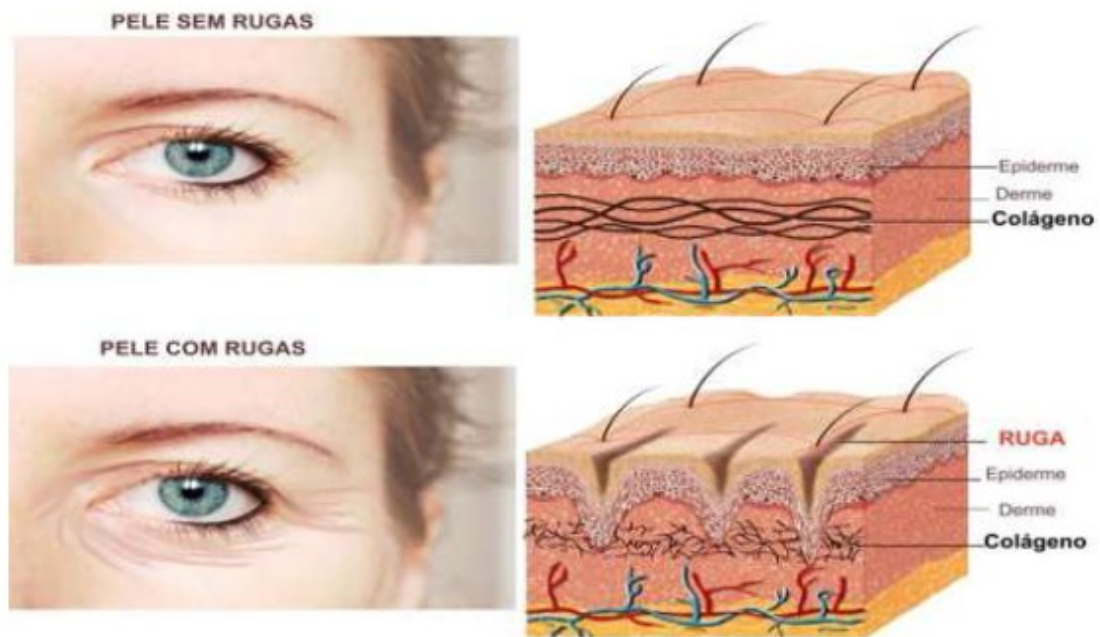
1.1.2 Skin aging

Aging is a complex and multifactorial process, involving morphological, physiological, biochemical, aesthetic and functional changes, resulting in a decrease in the biological functions of the human body, resulting in visible changes in the appearance of the skin over time, due to the degradation of its structural components. , variation in texture and color, thus characterizing visible aging of the skin, the appearance of wrinkles, sagging, spots, decreased tissue regeneration capacity, loss of tone, hydration, radiance, increased capillary fragility and of skin roughness, figure 3. Aging is classified as intrinsic or chronological, this is predictable, progressive and inevitable, chronologically aged skin presents pallor, dryness, fine wrinkles, sagging, reduction of adipose tissue, alopecia and benign skin tumors (SANTONI, 2018; HOORENS; ONGENAE, 2012; SALLES, *et. al.*, 2011; DA ROCHA BRITO; FERREIRA, 2018).

Extrinsic aging or photo aging originates and is cumulative from factors such as chronic exposure to ultraviolet radiation (UV), pollution, infrared radiation, physical inactivity, poor diet, stress, alcohol and tobacco consumption. Photo-aged skin presents wrinkles, freckles, lentigines, telangiectasias, superficial and deep rhytides, benign skin tumors, malignant neoplasms, hyperpigmentation, hypopigmentation, with guttate hypomelanosis being the most common (SANTONI, 2018;

HOORENS; ONGENAE, 2012; SALLES *et. al.*, 2011). Rhythms are classified as dynamic, which arise due to facial expressions and repetitive movements, static rhytides arise from the fatigue of skin structures, and gravitational rhytids are related to sagging and tissue ptosis (SANTONI, 2018; HOORENS; ONGENAE, 2012; SALLES *et. al.*, 2011).

Figure 3–Young skin versus aged skin



Source: DA ROCHA BRITO; FERREIRA, 2018

Approximately 80% of facial aging is related to photoaging, whose main villains are free radicals, these are unstable oxygen molecules that arise due to oxidative stress caused by the presence of various factors, such as stress, solar radiation, pesticides, cigarette smoke and pollution. The accumulation of free radicals generates changes in the components of connective tissue, which include an increase in the proliferative activity of fibroblasts, reduction and disorganization of collagen and elastin fibers and a decrease in hyaluronic acid in the skin (SANTONI, 2018; HOORENS ; ONGENAE, 2012;*et. al.*,2011;GARBUGIO; FERRARI, 2010).Some authors mention that regardless of the causes of skin aging, there are some characteristics that must be considered, see the table below:

Table 1- Location of the peculiarities of skin aging

Author	Location	Characteristics
- SANTONI (2018) - HOORENS; ONGENAE, (2012) - SALES <i>et. al.</i> , (2011)	Epidermis	- Flattening of the dermoepidermal junction. - Reduction in the number of melanocytes of 8 to 20% per decade, from the age of 30, which can result in hypochromia. - Activation of melanocytes in some cases causing hyperchromia. - Decrease in intercellular lipids such as: ceramics, cholesterol and fatty acids, functionally fundamental in the skin barrier, this decrease makes the skin susceptible to transepidermal water loss, causing flaking, cracks and dryness.
- SANTONI (2018)	Dermis	- Flattening of the dermal papillae. - Compromise of cellular nutrition. - Reduction in the number of fibroblasts. - Decrease of 1% per year in the production of collagen and elastin. - Regression of vascularization. - Reduction of glycosaminoglycans (HA).
- SANTONI (2018)	Tissue subcutaneous	- Reduction of adipose tissue on the face, back of the hands and anterior tibial region. - Accumulation of adipose tissue in the abdominal region.

Source: Developed by the author

Corroborating the authors' ideas, I highlight that there are several visible signs of skin aging, the main ones being: thick, yellowish skin, progressive appearance of superficial and deep wrinkles and furrows, and pigmented spots. Taking the above into account, some basic care is recommended to alleviate and delay the signs of aging, such as healthy eating habits, water intake and cosmetics, including fillers, as the main aid in treating the signs of aging. , with emphasis on AH.

2.2 FACIAL FILLERS

Filling is an aesthetic procedure for skin rejuvenation, injectable, modern, but non-surgical, indicated for the treatment of furrows, static wrinkles, atrophic scars and to improve facial contour, it can also be used to increase the volume of the lips and correct nasal deformities. Currently widely used in rejuvenation therapy, as its results are perceived from the first

application, in addition to the advantage of not being an invasive method, that is, hospital admission or general anesthesia is not required. (NERI *et. al.*, 2013; TAMURA, 2013; GUTMANN; DUTRA, 2018). Fillers are used taking into account the purpose of the application, it reaches from the superficial dermis, through the deep dermis and reaches the subcutaneous tissue, generally local or topical anesthesia is used. For lip filling, infraorbital nerve block anesthesia is used, applying anesthesia to the canine region, in addition, anesthesia of the labial frenulum and commissures must be performed, using an infiltrative anesthetic technique, similar to dental anesthesia. The application of fillers can be done in clinics and offices. Among the various facial fillers, one of the most used is hyaluronic acid, due to its practical application, good safety margin and excellent compatibility (NERI *et. al.*, 2013; TAMURA, 2013; GUTMANN; DUTRA, 2018).

2.2.1 Hyaluronic Acid (HA)

The first studies on HA began in 1934, in the ophthalmological biochemistry laboratory at Columbia University, Karl Meyer and John Palmer, isolated HA from bovine vitreous humor, in the 40s, Meyer and collaborators isolated HA present in the skin, joints, umbilical cord and cockscomb. In 1937, Kendall, Heidelberger and Dawson found that the polysaccharide in the capsule of the hemolytic group A *Streptococcus* bacteria and HA had great similarities, thus initiating research into HA of microbial origin. In 1950, Meyer and his team investigated the morphology of HA and exposed its properties. It is a linear polysaccharide with a high molar mass, formed by polyanionic disaccharide units of Dglucuronic acid (GlcUA) and Nacetylglucosamine (GlcNAc) linked (SANTONI, 2018; PAN *et. al.*, 2013; GARBUGIO; FERRARI, 2010)

The term Hyaluronic Acid derives from the Greek with the word *hyaloid* which means vitreous, it is the precise description of the appearance of HA, as *hyaloid* means transparent relative to glass. Uronic acid, a monosaccharide that composes it, is also the inspiration for the term HA. Hyaluronic acid is from the family of non-sulfated glycosaminoglycans, it is a molecule that is already present in the human body, being responsible for attracting and retaining water around it,

thus providing more radiance, firmness and texture to the skin. Some of its peculiarities distinguish hyaluronic acid from other fillers, such as its particle size, its greater viscoelasticity, the difference in polymer chain length and the type and density of *crosslinker*, to obtain better accommodation of the product on the skin, without risk of migration to other locations (GUTMANN; DUTRA, 2018; REQUENA *et. al.*, 2011; CROSS; ALVES; ALESSI, 2012; SANTONI, 2018).

The total amount of HA in the body is estimated at 12 grams, the majority of which is in the skin, around 7g, it is what provides volume, support, hydration and elasticity to the skin and its lowest concentration is in the blood. Hyaluronic acid is one of the most hygroscopic molecules known to date, as it has the ability to bind water up to 1000 times its volume. Taking this fact into consideration, it is understood that HA is extremely relevant for the skin, due to its moisturizing and plumping capacity, contributing to maintaining and recovering skin elasticity (SANTONI, 2018)

Because of its thick, gelatinous consistency and its high degree of hydration, HA acts as a gap filler in the dermis, absorbing shocks and providing stabilization, in addition to contributing elastic properties to form the network of helical structures. Due to its biological properties of lubrication, viscoelasticity, liquid retention, biocompatibility and biodegradability, HA is portrayed in the literature as a powerful moisturizer and restorer of facial skin, with its hydration potential being greater than other polysaccharides, it influences the proliferation cellular differentiation and tissue repair, generating changes in the availability and synthesis of HA (SANTONI, 2018).

By restoring HA in the deep layers of the skin, it is possible to restore water balance, filtration, regulation and distribution of proteins in tissues and a physical environment where cells move is formed, cooperating to improve the structure and elasticity of the skin. , smoothing wrinkles and expression lines, enhancing and restoring facial volume, creating lip volume and providing facial rejuvenation. Suppliers sell hyaluronic acid in a needled syringe in the form of a dense, non-particulate colorless gel and can be stored at room temperature, as can be seen in figure 4. There is no need for a skin test before application. As HA is a non-permanent filler, it lasts an average of 6 months, for this reason, to prolong the duration of HA, stabilization is carried out using the filling technique. *crosslinking*, in this technique

the molecules that bind to HA produce more stable macromolecules but with the same biocompatibility, making it necessary to calculate the ideal level of *crosslinking*, because the higher the level of crosslinking, the lower the hydrophilic property of HA, therefore its effectiveness will be reduced (GUTMANN; DUTRA, 2018; GUTOWSKI, 2016; SANTONI, 2018).

Figure 4- Syringe with 40G needle containing hyaluronic acid



Source: GUTMANN; DUTRA, 2018

Industrial HA is sold in the form of a thick, non-particulate, colorless gel in a needled syringe and can be stored and preserved at room temperature, but without freezing. It is important, however, to avoid exposing hyaluronic products to heat, as this can stimulate the formation of monomers, potentially contributing to inflammation (PAN *et. al.*, 2013; REQUENA *et. al.*, 2011; OLIVEIRA, 2021).

2.2.1.1 *Technique, locations and products for applying HA*

Hyaluronic acid in the form of an injectable gel is the most used in aesthetic approaches and provides the best results. It is generally used to treat wrinkles, correct facial contour and replace facial volume, filling nasojungal folds (dark circles), of nasolabial folds ("Chinese mustachë), in the periocular region ("crow's feet"), increased lip volume, marionette line, malar region, mandibular region, chin, neck and hands, scar, and is also used in rhinomodeling. The amount of HA to be injected for good correction depends on the depth of the furrows, wrinkles and also the viscosity of the acid used. There are several options on the market, and the choice of HA must consider aspects such as: biological compatibility, safety, stability at the site of application, low risk of allergy, not developing an inflammatory reaction, not being carcinogenic, not being removed by phagocytosis, be easy to apply, result in a natural appearance, low immunogenicity, reabsorption time, the way the product is obtained and the

cost to the patient. These are the characteristics expected from dermal fillers, all of which are met by AH, which makes it a product accepted worldwide for temporary dermal fillers, figure 5 (GUTMANN; DUTRA, 2018; GUTOWSKI, 2016; SANTONI, 2018; OLIVEIRA, 2021).

Figure 5- Application of Hyaluronic Acid



Source: (OLIVEIRA, 2021).

Among the HA available on the market, we can mention Hylaform® (Genzyme Corporation, USA) of animal origin, obtained from the rooster's comb, its concentration is 5.5 mg/ml of HA, while Restylane® and Perlane® (Galderma) do not have animal origin, and are produced by bacterial fermentation of Streptococcus, with a concentration of 20 mg/ml of HA, Juvéderm® (Allergan Industrie SAS, France) and Surgiderm®, have non-animal origin, are produced by bacterial fermentation of Streptococcus and its concentrations range from 18 mg/ml to 24 mg/ml of HA, Belotero® (Anteis AS, Switzerland) has non-animal origin and a concentration of 20 mg/ml to 26 mg/ml of HA, finally Redexis® (Prollenium Medical Technologies, Canada) has non-animal origin, is produced by bacterial fermentation of Streptococcus, with a concentration of 17 mg/ml and 25 mg/ml of HA, among others (GUTMANN; DUTRA, 2018; GUTOWSKI, 2016; SANTONI, 2018; OLIVEIRA, 2021).

Before undergoing the procedure, the patient must undergo an assessment to find out not only about their expectations and possible results, but also to check their health history, checking for possible contraindications, and the patient's history in relation to disorders must be investigated. bleeding, herpes, autoimmune diseases, pregnancy, allergies, tendency to form keloids and use of medications, such as anticoagulants, the type of filler most suitable for the specific needs of the patient must be defined.

patient, the technique that will be used and what the costs of the procedure will be, photographic documentation must also be carried out to record the appearance of the patients before the procedure, as well as to allow better analysis of specific critical areas, possible asymmetries and comparison with the result final (GUTMANN; DUTRA, 2018; GUTOWSKI, 2016; SANTONI, 2018; OLIVEIRA, 2021).

Application is made to the superficial, medium and deep dermis. The depth of application will depend on the viscosity of the product, and the more fluid the product, the more superficial its application should be, therefore, the more superficial the application, the greater the risk of visibility. As a result, several HA products began to be used on different parts of the face, due to the difference in residence time, persistence, injection and need for local anesthesia. To allow greater comfort for patients, pre-treatment with topical anesthetic formulations is necessary for 30 minutes before the procedure. Immediately beforehand, asepsis is performed with 4% alcoholic chlorhexidine. Some brands of HA have an anesthetic in their formulation, lidocaine, making the topical use of anesthetic unnecessary (GUTMANN; DUTRA, 2018; GUTOWSKI, 2016; SANTONI, 2018; OLIVEIRA, 2021).

The most used application technique is retro injection or retrograde injection, where the entire length of the needle is introduced into the area to be treated, injecting the material while removing the needle, a technique commonly used in the glabella line, nasolabial folds, lips and lacrimal groove, among others. The fan technique is similar to the retrograde technique, as soon as the needle is completely removed from the skin, it is reinserted in another direction, and the product is injected again in a retrograde route. This process is repeated numerous times in different directions until the appropriate correction is achieved. This approach is particularly useful in malar augmentation, but is also used in nasolabial fold correction. In the crossed lines technique (net or mesh), injections are performed parallel to each other, subsequently crossed injections perpendicularly with the initial parallel lines, proposing the filling of large areas or for the restoration of volume, being also used for marionette lines and increase of cheek (GUTMANN; DUTRA, 2018; GUTOWSKI, 2016; SANTONI, 2018; OLIVEIRA, 2021). In the serial punctual technique, the application is made point by point, being carried out at very close points to prevent irregularities. This technique is generally used to correct the lacrimal groove, in

lip augmentation and the treatment of other wrinkles and folds. Techniques can be combined during filling. After the product is injected, the area can be shaped with your fingertips to smooth out any irregularities. Therefore, the correct technique is crucial; Injections that are too shallow can cause visible irregularities and nodules, while injections that are too deep can be ineffective. Filling with HA does not require special care and does not interfere with the patient's routine. Ice can be used immediately after application and even the next day, if necessary. Manipulation of the treated area should be avoided, physical exercise and sun exposure and other sources of heat or cold, on average, it is recommended to apply 1 ml to the same anatomical region, maximum 2 ml, in 80% of patients, this is generally sufficient use 1 ml of product. If more product is needed, a booster is suggested in another treatment session (GUTMANN; DUTRA, 2018; GUTOWSKI, 2016; SANTONI, 2018; OLIVEIRA, 2021).

2.2.1.2 Risks of applying hyaluronic acid

Although facial fillers have a very favorable safety profile, there is no filler that is completely risk-free, and even experienced professionals may encounter immediate reactions, such as erythema, bleeding, nodulation and necrosis. Therefore, it is of great importance to know the possible complications that may occur in this procedure; the professional must be able to identify, classify and know how to treat them (GUTMANN; DUTRA, 2018).

2.2.1.3 Early side effects of hyaluronic acid

This acid is considered the gold standard in aesthetic procedures for correcting wrinkles, loss of contour and replacement of facial volume. Although it is a substance that is degradable by the body and most of its adverse effects are simply unsightly, complications require effective and rapid treatment in order to reduce the risk of sequelae or morbidities (GUTMANN; DUTRA, 2018). Still being considered safe, the HA dermal implant is not free from risks or adverse reactions, such as inflammatory reactions, small bruises, erythema, infection, nodules, abscesses in the

application sites, hypertrophic scars, tissue necrosis resulting from intravascular application or compression of the adjacent vascular network, persistent edema and granulomas. It should be noted that persistent edema and granulomas can be triggered by allergy to material containing divinyl sulfone and butanediol-diglycidyl-ether, or an immunological response to the protein components present in HA preparations. These complications can be treated with local application of hyaluronidase (FERREIRA; CAPOBIANCO, 2016; CROCCO; ALVES; ALESSI, 2012; TAMURA, 2013; GUTMANN; DUTRA, 2018; GUIMARÃES, 2021)

Complications may also be due to the inexperience of the applicator, incorrect technique or inherent to the product itself, considering its different origins, formulations and concentrations (CROCCO; ALVES; ALESSI, 2012; FERREIRA; CAPOBIANCO, 2016). The glabella is considered a risk area, due to the possibility of significant vascular compromise, leading to serious side effects, such as tissue necrosis and even blindness. The supratrochlear and supraorbital vascular bundles, where the branches of the internal carotid artery are located, supply the glabella, the nasal wall and the central-inferior portion of the forehead. Tissue necrosis in these territories can occur due to intravascular injection, compression by large volumes of HA and/or vascular injury, reducing local blood supply. There are, however, other hypotheses for the embolization path causing blindness from fillings in the medial and lateral forehead. There are reports of cerebral ischemia due to the diffusion of the injected material into the territory of the internal carotid artery (FERREIRA; CAPOBIANCO, 2016; CROCCO; ALVES; ALESSI, 2012; TAMURA, 2013; GUTMANN; DUTRA, 2018; GUIMARÃES, 2021)

Side effects can be divided into early and late. Erythema and edema are generally immediate and observed in most cases, occurring due to local inflammation in response to tissue injury and the hydrophilic property of HA. They can also be aggravated by multiple injections, thick material and incorrect application technique. To provide relief, apply ice for five to ten minutes and keep your head elevated. It usually resolves within hours or in one or two days. Edema can be avoided or minimized by using anesthetic with epinephrine, cold compresses and fewer skin pricks. Ecchymosis/hematoma usually occurs immediately due to perforation of small vessels at the application site or due to compression and secondary rupture of the vessels. Immediate local compression must be performed

(FERREIRA; CAPOBIANCO, 2016; CROCCO; ALVES; ALESSI, 2012; TAMURA, 2013; GUTMANN; DUTRA, 2018; GUIMARÃES, 2021)

There is a greater risk of heavy bleeding if deep vessels rupture. It is recommended to apply in a place with good lighting to avoid perforating the vessels. It is important to know that fillers associated with lidocaine promote vasodilation and may increase the risk of local bleeding. They generally improve in five to ten days and do not affect the final result. In cases of profuse bleeding, cauterization of the vessel may be necessary. Necrosis is a rare complication, caused by local compression, overcorrection, intense inflammation or accidental intra-arterial application, with vascular embolization. Reported cases occurred in the area of the angular, nasolabial and supratrochlear arteries. There is no consensus regarding the ideal treatment in these cases, but it is important to take local hygiene care, apply warm compresses, local massage to dissolve the plunger and 2% nitroglycerin paste (FERREIRA; CAPOBIANCO, 2016; CROCCO; ALVES; ALESSI, 2012; TAMURA, 2013; GUTMANN; DUTRA, 2018; Injection of hyaluronidase as early as possible, within the first 24 hours of the procedure, is also described, reducing the damage caused by necrosis. In the case of embolization, full heparinization of the patient can be performed. Venous occlusions are generally later, with slower evolution, with less local pain and a bluish tone to the skin. The infection is probably due to product contamination or inadequate patient aseptic technique. The authors believe that contamination occurs due to poor skin hygiene. Nodules are generally observed in the short and medium term, manifesting as whitish or normochromic papules. They occur most often due to poor application technique and very superficial HA injection. Treatment can be done with local massage, and in extreme cases oral corticosteroids are indicated. In severe cases, surgical removal of the material may be performed. Fortunately, most cases resolve spontaneously (FERREIRA; CAPOBIANCO, 2016; CROCCO; ALVES; ALESSI, 2012; TAMURA, 2013; GUTMANN; DUTRA, 2018; GUIMARÃES, 2021)

Granulomas occur in 0.01 to 1% of cases, between six and 24 months after the application of fillers. They appear as palpable, non-painful nodules along the way the fillers are applied. It is believed that these reactions occur due to the presence of impurities in the bacterial fermentation process in the production of hyaluronic acid and are not due to

hypersensitivity to the product itself. The treatment is controversial, and hyaluronidase can be applied with concentrations ranging from 50U/mL10 to 150U/mL17 or intralesional corticosteroid infiltration (FERREIRA; CAPOBIANCO, 2016; CROCCO; ALVES; ALESSI, 2012; TAMURA, 2013; GUTMANN; DUTRA, 2018; GUIMARÃES, 2021).

Allergic reactions are described in 0.1% of cases, starting between three and seven days after application of the product, a period, however, that can extend to a period of one to six months, the treatment described is with corticosteroids oral or intralesional corticosteroid infiltration. Hypertrophic scars may be at skin puncture sites and may be related to a history of keloids. Treatment is with occlusive corticosteroids. Contraindications for filling with HA are pregnancy, lactation, systemic autoimmune diseases and immunosuppression, coagulation disorders or use of anticoagulants, inflammation or infection in the area to be treated and patients with behavioral disorders (FERREIRA; CAPOBIANCO, 2016; CROCCO; ALVES ; ALESSI, 2012; TAMURA, 2013;

3 METHODOLOGY

For the present study, the following procedures were carried out: A bibliographical search was carried out in the main databases: Virtual Health Library (VHL); Scientific Electronic Library Online (SciELO) and Lilacs. Considering that the purpose of this work is to carry out a descriptive approach about the general aspects, application techniques and possible complications in the use of hyaluronic acid in biomedicine. The following keywords were used: fillers, facial aging, hyaluronic acid and aesthetic biomedicine.

The bibliographic research was carried out in the period between December 1, 2020 and April 11, 2021 using materials published in the last 10 years. For inclusion criteria, the materials should be related to the theme; materials located in the bibliographic research that did not include any of the previously described criteria or that did not have references available were not selected for inclusion in this article.

4 RESULTS AND DISCUSSIONS

The study of current literature shows that HA is generally an effective alternative for the treatment of facial aging, providing volume, support, hydration, and elasticity to the skin, thus improving its structure and expression lines. Its use has become very frequent, due to its ability to act as a dermal filler to correct lips, cheekbones, chin and other imperfections, thus replacing facial volume lost over the years. There are still few scientific studies that prove the long-term resistance of hyaluronic acid or that provide data that prove the durability of each product. On the other hand, we have a large number of commercial presentations available on the market. This work has become important for delving deeper into the topic, as it allows us to better understand the function, durability and effects of hyaluronic acid.

It is known that the use of HA for aesthetic treatments, such as facial harmonization, has been growing in recent years. Despite being considered safe and effective due to its biocompatibility, attention must be paid to the risks and possible complications, early and late: inflammatory response, erythema, edema, sensitivity, pain, nodulations, ulcerations, crusts, necrosis, vascular embolism, blindness, biofilm formation, granuloma, among others. Therefore, for proper use, qualified professionals are needed, with extensive knowledge of facial anatomy and understanding of the individual clinical history. It is important to evaluate the risks and benefits of this application and inform the patient of all possibilities of adverse effects, so that a joint and conscious decision can be made.

FINAL CONSIDERATIONS

It is known that skin aging is a natural, gradual and continuous process, determined by intrinsic and extrinsic processes. Over time, these changes lead to a decline in collagen, elastin and fibroblast levels and consequently HA is also found in low concentrations, with loss of elasticity and flexibility and subsequent formation of wrinkles and dehydration. A product to delay aging, injectable HA, can improve facial appearance,

as it has several benefits and functions such as volume, support, hydration and elasticity. As a temporary implant, HA has been widely used as a practical procedure that restores the appearance of healthy skin and improves facial lines and wrinkles.

There are several laboratories that manufacture products based on this acid; and when used in a minimally invasive way, it may present some side effects, but few articles reported serious complications, since HA is part of the natural constitution of the dermis. The application of HA has grown, but qualified professionals such as: doctors, biomedical scientists, pharmacists and dentists must take due care in its application, as well as highlight to their patients the effects of the active ingredient so that they can perceive the results promised in the restoration of facial filler. Therefore, HA is a good adjunct to delay facial aging, combating signs of aging, enabling younger-looking and hydrated skin.

REFERENCES

CROCCO, EI; ALVES, RO; ALESSI, C. Adverse events of injectable hyaluronic acid. **Surgical & cosmetic dermatology**, v. 4, no. 3, p. 259-263, 2012.

DA ROCHA BRITO, DC; FERREIRA, LA Study of pre-formulation of gel containing hyaluronic acid in microvibrating massage packaging. **Psychology and Health in debate**, v. 4, no. 1, p. 130-146, 2018.

DANTAS, S. Fonseca Ingênito Moreira *et. al.* The short and long-term effectiveness of hyaluronic acid fillers in facial rejuvenation. **Health & science in action**, v. 5, no. 1, p. 63-81, 2019.

ESMERALDO, Arthur Rafael Amorim Alves *et. al.* Interactive virtual atlas of histology and cell biology. 2014.

FERREIRA, NR; CAPOBIANCO, MP Use of hyaluronic acid to prevent facial aging. **UNILAGO Scientific Magazine**, v. 1, no. 1, p. 1-10, 2016.

GARBUGIO, AF; FERRARI, GF The benefits of hyaluronic acid in facial aging. **UNINGÁ Review Magazine**, Paraná, vol. 2, no. 4, p. 25-36, 2010.

GUIMARÃES, ACRC *et. al.* Deleterious effects of using hyaluronic acid for aesthetic purposes. **Brazilian Journal of Health Review**, v. 4, no. 2, p. 6103-6115, 2021.

GUTMANN, IE; DUTRA, RT Adverse reactions associated with the use of facial fillers with hyaluronic acid. **Electronic magazine biosciences, biotechnology and health**, v. 11, no. 20, p. 7-17, 2018.

GUTOWSKI, KA Hyaluronic Acid Fillers. **Clin Plast Surg**, v. 43, no. 3, p. 489-96, 2016.

HOORENS, I.; ONGENAE, K. Primary focal hyperhidrosis: current treatment options and a step-by-step approach. **Journal of the European Academy of Dermatology and Venereology**, v. 26, no. 1, p. 1-8, 2012.

JUNQUEIRA, LC; CARNEIRO, J. Basic Histology: Text and Atlas. 12. **Koogan**, Guanabara, p. 568, 2013.

MONTANARI, T. **Histology**: text, atlas and script for practical classes. 2016.

NAYLOR, EC; WATSON, RE B; SHERRATT, MJ Molecular aspects of skin aging. **Maturitas**, v. 69, no. 3, p. 249-256, 2011.

NERI, SRNG *et. al.* The use of hyaluronidase in complications caused by hyaluronic acid for facial volumization: case report. **Surg Cosmet Dermatol**, v. 5, no. 4, p. 364-6, 2013.

OLIVEIRA, C.S. *et. al.* Phototherapy, care and nursing performance. **UNICIENCES**, v. 15, no. 1, 2011.

PAN, N.C. *et. al.* Hyaluronic acid: characteristics, microbial production and industrial applications. **BBR-biochemistry and biotechnology reports**, v. 2, no. 4, p. 42-58, 2013.

PAPAZIAN, M.F. *et. al.* Main aspects of facial fillers. **Faipe Magazine**, v. 8, no. 1, p. 101-116, 2018.

PEREIRA, KP; DELAY, CE Hyaluronic acid in facial hydration. **Tuiuti University of Paraná**, 2017.

REQUENA, L. *et. al.* Adverse reactions to injectable soft tissue fillers. **Journal of the American Academy of Dermatology**, v. 64, no. 1, p. 1-34, 2011.

RED, AP **Skin Aging**: influencing factors, active ingredients and delivery strategies. 2014. Doctoral Thesis. [sn].

SALLES, AG *et. al.* Clinical and skin thickness assessment one year after hyaluronic acid filler. **Brazilian Journal of Plastic Surgery**, v. 26, no. 1, p. 66-69, 2011.

SANTONI, MT **Use of injectable hyaluronic acid in facial aesthetics**: a review of the literature. 2018.

SOUSA, NF da S.*et. al.* Active aging: prevalence and gender and age differences in a population-based study. **Public health notebooks**, v. 34, p. e00173317, 2018.

TAMURA, BM Facial topography of filler injection areas and their risks. **Surgical & Cosmetic Dermatology**, v. 5, no. 3, p. 234-238, 2013.