



## ALLERGIC DERMATITIS TO ECTOPARASITE BITE (DAPE): CASE REPORT AND USE OF CHLORPYRIFOS

### ALLERGIC DERMATITIS TO ECTOPARASITE BITE (DAPE): CASE REPORT AND USE OF CHLORPYRIFOS

Mariana Silvestre Donatilio - Serra Dourada College

Wanessa Ferreira Boabaid

#### SUMMARY

In the clinical practice of small animals, cases of dermatitis in dogs are common. Atopic dermatitis caused by ectoparasite bites is one of the most common dermatological pathologies in dogs and cats, and is associated with the salivary protein of these parasites. The objective of this study is to present a clinical case of FAD in a canine, contextualized by a literature review on the pathology. The case report will detail the diagnosis, treatment and management of the affected animal. It is concluded, based on the literature and the description, that ectoparasite control is the main treatment for dermatitis.

**Keywords:**Flea.Dermatology. Small animals.

#### ABSTRACT

In clinical practice with small animals, cases of dermatitis in dogs are common. Atopic dermatitis caused by ectoparasite bites is one of the common dermatological pathologies in dogs and cats, being associated with proteins in the saliva of these parasites. The objective of this work is to present a clinical case of DAPP in a canine, contextualized by a literature review on the pathology. In the case report, the diagnosis, treatment and management of the affected animal will be detailed. It is concluded, based on the literature and the description, that the control of ectoparasites is the main treatment for dermatitis.

**Keywords:**Flea. Dermatology. Small animals.

#### 1. INTRODUCTION

Dermatological pathologies are common in veterinary medical routine. Dermatitis associated with ectoparasites is frequent in dogs, affecting their quality of life, as it increases itching and discomfort with the parasites. The flea is seen as the main causative agent due to a protein in its saliva that causes sensitivity in the host animal (Moraes, 2021, p.3; Silva et al, 2012, p.2).

The main objective of this research is to describe a clinical case of a dog that presented sensitivity to flea bites and successfully controlled the dermatitis. In addition, the specific objectives are to describe the etiology and pathophysiology of DAPE; elucidate the main clinical signs presented; and clarify the means of diagnosis.

For this purpose, a brief and descriptive bibliographical research on the main characteristics of the pathology was used. Using Google Scholar and SciELO as databases, the inclusion criteria aimed at current research between 2012 and 2023, with priority given to research from the last five years. The exclusion criteria included outdated research (after 2012) and that deviated from the main theme of this project.

#### 2 THEORETICAL FRAMEWORK

##### 2.1 ETIOLOGY AND PATHOPHYSIOLOGY

1

Dermatological cases are the most frequent in the clinical routine of small animals, with approximately 50% of dermatological consultations associated with allergic dermatitis (TECSA, 2020). This pathology is seasonal, directly related to the cycle of ectoparasites such as fleas (main causative agents) and ticks (Moraes, 2021, p.2).

Its greatest occurrence is in the summer, as it is hot and humid. However, in tropical regions this dermatopathy can be perennial, as the climate constantly favors the proliferation of these ectoparasites. The clinical presentation manifests in animals between 3 and 5 years of age, and there is no sexual predisposition, but some



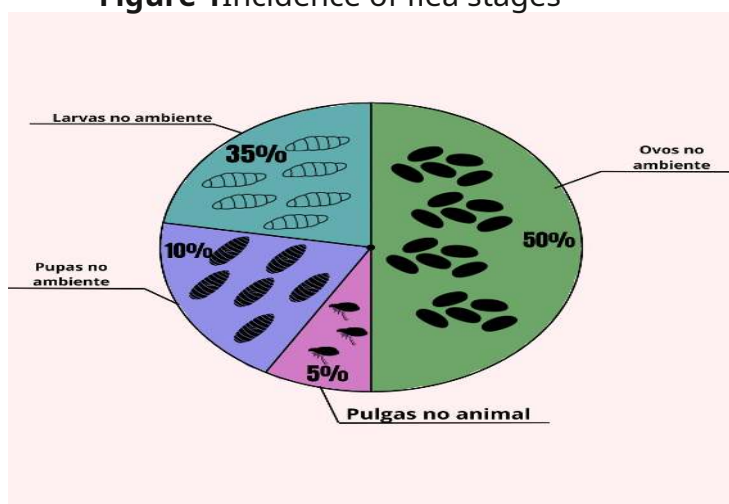
breeds tend to present such allergies more easily, such as Chow Chow, Pyrenean Shepherd, Fox Terrier, Pekingese and Spaniel (Moraes, 2021, p.4).

This pathology consists of a chronic inflammation of the epithelial tissue, mainly affecting dogs. The allergic process occurs through the inoculation of flea saliva when they take a blood meal - feeding - the anticoagulant components and the protein present stimulate the animal's immune system, initiating the allergic process (Silva *et al*, 2012, p.2).

It is important to highlight that each animal has its own pruritus threshold and when exceeded, clinical signs appear. Hypersensitivity to flea saliva appears from a low molecular weight hapten and two allergens with a higher weight that increase the collagen binding of the dermis, leading to the appearance of DAPE (Martins, 2022, p.13).

Approximately 80% of dogs are sensitive to the antigen known as Cte f1, which stimulates the IgE response, attacking the skin barrier and predisposing them to environmental allergens. The main species of fleas found in the country are: *Ctenocephalides felis* and *Ct. canis*, and its complete cycle varies from 12 days to 190 days depending on the climate, with an ideal temperature between 21° and 27°C (Martins, 2022, p.14). Its development takes place in the environment and it only feeds on the animal, from which Figure 1 was developed.

**Figure 1** Incidence of flea stages



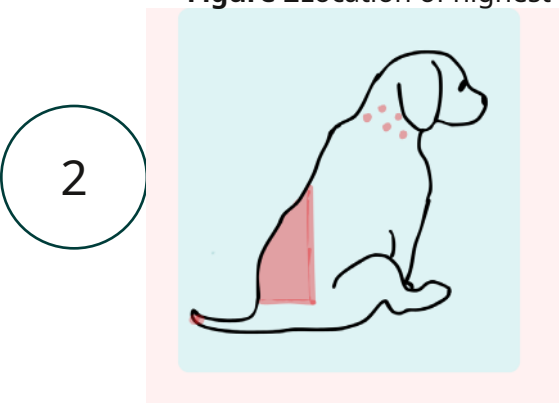
Source: Own authorship

Based on the figure, it is possible to note that in addition to controlling fleas on the animal, it is important to recommend cleaning the environment. These ectoparasites undergo metamorphosis and their eggs do not adhere to the animal's fur, being deposited in moist and warm cracks in the environment (Martins, 2022, p.15).

## 2.2 CLINICAL SIGNS AND CLINICAL DIAGNOSIS

The caudodorsal lumbosacral area (Figure 2) is the main area for the appearance of clinical signs, but it can also appear in the caudomedial tip of the thighs, abdomen and flanks. The clinical presentation of DAPE is seen as intense pruritus, papular and crusted eruptions, leading to seborrhea, alopecia, hyperpigmentation of the affected areas and may cause pyoderma (Oliveira *et al*, 2012, p.1; TECSA, 2020).

**Figure 2** Location of highest incidence of DAPE injuries



When there is a very high degree of infection of the dermis, the animal begins to present an intense odor caused by pathogens secondary to the allergy, such as *Malassezia dermatitis*, *Sarcoptes scabiei* and *Demodex spp*, intensifying pruritus and lesions, worsening the patient's prognosis (Hensel et al, 2015, p.4).

Clinically, the lesions are highly suggestive due to their morphology and location, and can be combined with the patient's clinical history and physical examination. According to Moraes (2021, p.7), the gold standard for diagnosing DAPE is the anamnesis and therapeutic response, but the TECSA Laboratory (2020) states that a laboratory test that identifies specific IgE to flea bites in a semi-quantitative serological assay using the ELISA method may be requested.

## 2.3 TREATMENT AND CONTROL

Treatment is essential to ensure relief from the animal's discomfort. If the lesions are infected, the use of anti-inflammatories and antibiotics is recommended. The use of commercial flea medications such as fluralaner and fipronil have a good therapeutic response in controlling the parasite. However, as the presence of these parasites is more common in the environment, cleaning and exterminating them is essential (Morais, 2021, p.11).

In addition, the use of prednisolone is recommended to control pruritus; if it is chronic, gradual withdrawal should be performed. Baths with antiseptic products to maintain infection control are recommended, such as chlorhexidine and anti-parasitic shampoos to reinforce the control of ectoparasites (Oliveira et al, 2012, p.3).

The use of Chlorpyrifos as a parasite control agent during the treatment of DAPE was not found in the literature. However, it is known that it is an organophosphate that acts to block and degrade acetylcholine by inhibiting acetylcholinesterase. It is a fat-soluble drug, being rapidly absorbed by the skin and mucous membranes and distributed throughout the body. It is oxidized by the liver and excreted by the kidneys (Barros; Stasi, 2012, p.482).

Improper use can lead to poisoning, causing abdominal pain, diarrhea, polyuria, sialorrhea, miosis, bradycardia and tremors. It is important to monitor the animal after placing the collar on it (Spinosa; Górnjak; Bernardi, 2023, 688).

## 3. MATERIAL AND METHOD

This research uses a qualitative approach, focusing on a systematic and objective literature review. Data collection was conducted primarily through Google Scholar, including studies published in the last five years, ensuring the current and relevant information. The articles selected were those that offer significant contributions to the understanding of the topic in question, with an emphasis on the practical applicability of the results in clinical decisions.

In addition to the literature review, a case study of a mixed breed dog (SRD), approximately 3 years old, will be presented. The case study will detail the clinical characteristics, the diagnostic process and the therapeutic interventions adopted, allowing an in-depth analysis of the clinical actions implemented in the management of the patient.

## 3. RESULTS AND DISCUSSION

A neutered dog, approximately 3 years old and weighing 15.1 kg, was treated at home. The main complaint reported was alopecia located in the lumbosacral and dorsal region, associated with intense itching, hyperpigmentation and inflammatory-looking excoriations (Figures 3 and 4).

3

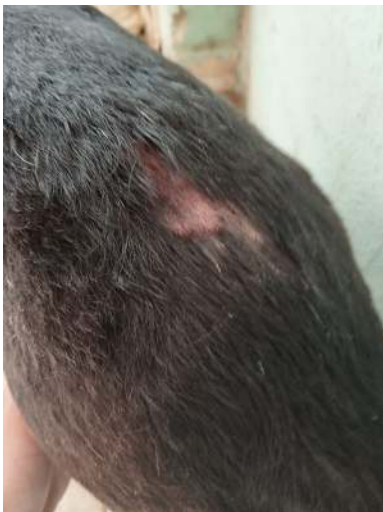**Figure 3** alopecia and abrasions



Source: Own authorship

When reviewing the patient's clinical history, the owner reported having difficulty combating ectoparasites in the area (which had low vegetation) and that she had four other dogs in the house, but only the one treated had alopecia (the other animals had pruritus).

**Figure 4** Excoriation



Source: Own authorship

It is possible to note that the symptoms presented by the patient are consistent with the literature. Oliveira et al (2012, p. 1) state in their research that the main symptoms of DAPE include alopecia and lumbosacral pruritus associated with skin hyperpigmentation. In addition, Moraes (2021, p. 4) mentions that as a result of irritation, the animal can self-harm, causing alopecia, abrasions, and seborrhea, similar to the case described in the present research.

During the physical examination of the patient, it was possible to observe normal heart and respiratory rates, temperature of 37.1°C, normal colored mucous membranes and normal skin turgor test. Although the parameters were found to be normal, when analyzing the animal a tick was found (*Rhipicephalus sanguineus*), with the owner's authorization, an inspection was carried out on all the animals in the residence, confirming infestation by ectoparasites.

Therefore, in the studies carried out by Hensel et al (2015, p.4) and Moraes (2021, p.5), the diagnosis of flea bite allergy dermatitis is made based on the anamnesis and response to the therapy instituted. Based on this, the veterinarian in charge suggested this pathology, starting drug treatment with prednisolone 10 mg SID for 6 days in order to reduce the pruritus.

Furthermore, rigorous cleaning of the environment with an ectoparasiticide solution containing deltamethrin was requested,

diluted 10ml/5L. The tutor was emphasized the importance of using protection when cleaning the area and keeping animals away from the cleaning area for 24 hours.

Based on this, in addition to environmental control, the use of flea collars was prescribed for all animals, with the flea collar of choice containing the active ingredient Chlorpyrifos. This ingredient acts by inhibiting the parasite's acetylcholine, affecting its development and leading to its death (Spinosa; Górnaiak; Bernardi, 2023, p.688).

Approximately 4 weeks after treatment with the anti-inflammatory and placement of the collar, the infestation by ectoparasites was declared under control. The animal experienced partial hair growth on the skin lesions (Figure 5), showing the effectiveness of the treatment instituted by the veterinarian.

**Figure 5** Full recovery of lesions and itching



Source: Own authorship

## FINAL CONSIDERATIONS

In view of the above, it is possible to conclude that the use of the collar with Chlorpyrifos was effective for the control of ectoparasites and management of allergic dermatitis caused by ectoparasite bites. In addition, management with steroidal anti-inflammatory drugs helps to control the animal's itching and discomfort.

Therefore, flea and tick control is essential for animals, reducing the incidence of pathologies such as the one described. Furthermore, knowledge of a good treatment protocol for FAD is important for professionals in the field, as it is considered common in the clinical routine of small animals.

## REFERENCES

BARROS, Ciro M.; STASI, Luiz Claudio D. *Veterinary Pharmacology*. Barueri: Manole, 2012. E-book. p.482. ISBN 9788520449981. Available at: <https://integrada.minhabiblioteca.com.br/reader/books/9788520449981/>. Accessed on: October 30, 2024.

HENSEL, P. et al. Canine atopic dermatitis: detailed guidelines for diagnosis and allergen identification. *BMC Vet Res* 11, 196 (2015). Available at: <https://doi.org/10.1186/s12917-015-0515-5>. Accessed on: October 15, 2024

5

MARTINS, Amanda. Control of flea allergy dermatitis (FAD) in dogs. 2022. Work Course Completion Certificate (Degree in Veterinary Medicine) – Veterinary Medicine Course, Anhanguera Institution. Available at: <https://repositorio.pgsscogna.com.br/handle/123456789/20833>. Accessed on: October 24, 2024.

MORAES, Lais de Jesus. Evaluation of the prick test as an auxiliary method in the diagnosis of flea bite allergy dermatitis in dogs. 2021. Dissertation (Master in Veterinary Sciences) – Institute of Veterinary Medicine, Federal Rural University of Rio de Janeiro, Seropédica, RJ. Available at: <https://tede.ufrj.br/jspui/bitstream/jspui/6556/2/2021%20-%20Lais%20de%20Jesus%20Moraes.pdf>. Accessed on: October 23, 2024.

OLIVEIRA, et al. Flea bite allergy dermatitis: case report. In: XV Unicruz Scientific Initiation Exhibition, 2020. Available at: <https://home.unicruz.edu.br/seminario/downloads/anais/ccs/dermatite%20alergica%20a%20picada%20de%20pulga%20relato%20de%20caso.pdf>. Accessed on: October 16, 2024.

SILVA, Nara Cristina et al. Flea allergy dermatitis – clinical diagnosis. Goiânia: Universidade Federal de Goiás, 2012. Available at: [https://files.cercomp.ufg.br/weby/up/399/o/NARA\\_CRISTINA\\_SIL-VA.pdf](https://files.cercomp.ufg.br/weby/up/399/o/NARA_CRISTINA_SIL-VA.pdf). Accessed on: October 15, 2024.

SPINOSA, Helenice de S.; GÓRNIK, Silvana L.; BERNARDI, Maria M. Pharmacology Applied to Veterinary Medicine. 7th ed. Rio de Janeiro: Guanabara Koogan, 2023. E-book. p.688. ISBN 9788527738941. Available at: <https://integrada.minhabiblioteca.com.br/reader/books/9788527738941/>. Accessed on: Oct. 30, 2024.

TECSA. Flea allergy dermatitis - DAPP. 2020. Available at: <https://www.tecsa.com.br/assets/pdfs/DERMATITE%20AL%3%89RGICA%20A%20PICADA%20DE%20PULGAS.pdf>. Accessed on: October 30, 2024.