RCMOS – Revista Científica Multidisciplinar O Saber. ISSN: 2675-9128. São Paulo - SP.
Ano VII, v.1 2026 | submissão: 23/07/2026 | aceito: 26/07/2026 | publicação: 29/07/2026

Colorectal Cavernous Hemangioma in a Young Patient: Diagnostic Challenge and Laparoscopic Treatment – A Case Report

Hemangioma Cavernoso Colorretal em Paciente Jovem: Desafio Diagnóstico e Tratamento Videolaparoscópico – Relato de Caso

Hemangioma Cavernoso Colorrectal en una Paciente Joven: Desafío Diagnóstico y Tratamiento Videolaparoscópico – Reporte de Caso

Leandro Moraes Costa – Getúlio Vargas University Hospital, Federal University of Amazonas, leandromedicinauea@gmail.com – General Surgeon, Resident Physician in Digestive Surgery. Manaus, Amazonas, Brazil.
Odair Machado Vaz – Getúlio Vargas University Hospital, Federal University of Amazonas – General Surgeon, Resident Physician in Digestive Surgery. Manaus, Amazonas, Brazil.
Rubem Alves da Silva Junior – Getúlio Vargas University Hospital, Federal University of Amazonas – Master's degree in Surgery, Digestive Surgeon. Preceptor and Technical Director of the Digestive Surgery Medical Residency Program. Manaus, Amazonas, Brazil.
Leury Max Santos Ferreira – Getúlio Vargas University Hospital, Federal University of Amazonas – Master's degree in Surgery, Colorectal Surgeon. Preceptor and Technical Director of the Coloproctology Service. Manaus, Amazonas, Brazil.

Abstract:
Colorectal hemangiomas are rare vascular malformations of the gastrointestinal tract and represent an uncommon cause of lower gastrointestinal bleeding, especially in young patients[1]. Diagnostic delay is frequent due to nonspecific symptoms and similarities with inflammatory bowel diseases[2]. We report the case of an 18-year-old female patient with recurrent hematochezia and iron deficiency anemia since childhood, initially diagnosed and treated as ulcerative colitis without adequate clinical response. After multiple hospital admissions due to lower gastrointestinal bleeding, colonoscopy revealed an extensive hemangioma involving the sigmoid colon, rectum, and anal canal. Histopathological examination confirmed cavernous colorectal hemangioma. The patient underwent laparoscopic proctosigmoidectomy with low colorectal anastomosis and protective ileostomy, associated with intraoperative colonoscopy for precise disease delimitation. The postoperative course was uneventful, with significant improvement in hematochezia, normalization of hematimetric parameters, and substantial improvement in quality of life. This case highlights the importance of considering vascular malformations in the differential diagnosis of recurrent lower gastrointestinal bleeding in young patients refractory to conventional inflammatory bowel disease therapy.

Keywords: Hemangioma; Lower gastrointestinal bleeding; Rectum; Sigmoid colon; Laparoscopy.

Resumo:
Os hemangiomas colorretais representam malformações vasculares raras do trato gastrointestinal, sendo causa incomum de hemorragia digestiva baixa, especialmente em pacientes jovens[1]. O atraso diagnóstico é frequente devido à inespecificidade dos sintomas e à semelhança clínica com doenças inflamatórias intestinais[2]. Relata-se o caso de paciente do sexo feminino, 18 anos, com história de hematoquezia recorrente e anemia ferropriva desde a infância, inicialmente diagnosticada e tratada como retocolite ulcerativa, sem resposta clínica adequada. Após múltiplas admissões hospitalares por hemorragia digestiva baixa, foi submetida à colonoscopia, que evidenciou hemangioma extenso acometendo sigmoide, reto e canal anal. O exame anatomopatológico confirmou hemangioma cavernoso colorretal. A paciente foi submetida à proctossigmoidectomia videolaparoscópica com anastomose colorretal baixa e

ileostomia de proteção, associada à colonoscopia intraoperatória para delimitação da extensão da doença. Evoluiu satisfatoriamente, com resolução importante da hematoquezia, normalização dos parâmetros hematimétricos e melhora significativa da qualidade de vida. O caso evidencia a importância do diagnóstico diferencial das malformações vasculares em pacientes jovens com hemorragia digestiva baixa recorrente refratária ao tratamento convencional para doença inflamatória intestinal.

Palavras-chave: Hemangioma; Hemorragia digestiva baixa; Reto; Sigmoide; Videolaparoscopia.

Resumen:
Los hemangiomas colorrectales representan malformaciones vasculares raras del tracto gastrointestinal y constituyen una causa infrecuente de hemorragia digestiva baja, especialmente en pacientes jóvenes[1]. El retraso diagnóstico es frecuente debido a la inespecificidad de los síntomas y a la semejanza clínica con las enfermedades inflamatorias intestinales[2]. Se presenta el caso de una paciente de 18 años, con antecedentes de hematoquecia recurrente y anemia ferropénica desde la infancia, inicialmente diagnosticada y tratada como portadora de colitis ulcerosa, sin respuesta clínica adecuada. Tras múltiples ingresos hospitalarios por hemorragia digestiva baja, se le realizó una colonoscopia que reveló un hemangioma extenso que afectaba el colon sigmoide, el recto y el canal anal. El examen anatomopatológico confirmó un hemangioma cavernoso colorrectal. La paciente fue sometida a proctosigmoidectomía videolaparoscópica con anastomosis colorrectal baja e ileostomía de protección, asociada a colonoscopia intraoperatoria para delimitar la extensión de la enfermedad. Evolucionó satisfactoriamente, con resolución importante de la hematoquecia, normalización de los parámetros hematimétricos y mejoría significativa de la calidad de vida. El caso evidencia la importancia del diagnóstico diferencial de las malformaciones vasculares en pacientes jóvenes con hemorragia digestiva baja recurrente refractaria al tratamiento convencional de la enfermedad inflamatoria intestinal.

Palabras clave: Hemangioma; Hemorragia digestiva baja; Recto; Colon sigmoide; Videolaparoscopia.

Introduction

Colorectal hemangiomas are rare vascular lesions of the gastrointestinal tract and account for a small proportion of the causes of lower gastrointestinal bleeding[1]. The rectum and sigmoid colon are the segments most frequently affected, especially in cases of diffuse cavernous hemangioma[2].

Although they are generally congenital in origin, many patients remain undiagnosed for years because of low clinical suspicion and nonspecific symptoms[3]. The predominant clinical manifestation is recurrent hematochezia, frequently associated with chronic iron deficiency anemia[4].

Because of their clinical similarity to more prevalent conditions, such as hemorrhoidal disease and inflammatory bowel diseases, diagnosis is often delayed, exposing patients to inappropriate treatments and multiple hospital admissions[2,5].

Colonoscopy plays a fundamental role in diagnostic suspicion, while complementary imaging tests help evaluate the extent of the disease and guide therapeutic planning[6]. Surgical treatment remains the main therapeutic modality in extensive or symptomatic cases, and the minimally invasive approach is a safe and effective alternative[1].

This study aims to report a case of cavernous colorectal hemangioma in a young patient previously diagnosed with ulcerative colitis, emphasizing the diagnostic challenges and laparoscopic treatment.

Case Report

Patient T.G.C.B., female, 18 years old, with a history of recurrent hematochezia and iron deficiency anemia since childhood, without other associated symptoms.

According to her mother, the patient began the diagnostic workup while still of school age and was initially followed by pediatric gastroenterology, receiving a diagnosis of inflammatory bowel disease, specifically ulcerative colitis. Since then, she had been using rectal mesalazine, without significant improvement in her clinical condition.

The patient experienced alternating periods of symptom improvement and exacerbation, progressing to multiple emergency department admissions because of episodes of lower gastrointestinal bleeding associated with marked asthenia and anemia requiring blood transfusion.

Given the persistence of the clinical condition and the absence of an adequate therapeutic response, colonoscopy was performed and revealed a large, flat vascular lesion involving the sigmoid colon, rectum, and anal canal, with no other associated abnormalities. Histopathological examination of the endoscopic biopsies confirmed the diagnosis of cavernous colorectal hemangioma.

Computed tomography angiography of the entire abdomen showed circumferential wall thickening of the rectum and rectosigmoid transition, apparently extending from the anorectal junction, with vascular prominence of the mesorectal plexus. No specific feeding vessel for the lesion was identified; however, distal branches arising from the inferior mesenteric artery and extending to the mesorectum were observed.

After preoperative evaluation and preparation, including blood transfusion because of symptomatic anemia, laparoscopic surgical treatment was chosen.

Laparoscopic proctosigmoidectomy with protective ileostomy was performed, associated with intraoperative colonoscopy to precisely delimit the extent of the disease and define the intestinal transection line.

During intraoperative colonoscopy (Figure 1), friable mucosa was observed, with extensive longitudinal involvement by ectatic, violaceous vessels affecting the anal canal, rectum, and distal third of the sigmoid colon, as well as areas of abrupt transition between affected mucosa and segments of normal sigmoid mucosa (Figure 2).

Laparoscopy showed a preserved-appearing serosa associated with ectatic subserosal vessels throughout the distal sigmoid colon and rectum, with no other relevant intra-abdominal abnormalities (Figures 3–4).

Proctosigmoidectomy was therefore performed with primary anastomosis between the colon and the residual rectum approximately 2 cm from the anal verge, associated with a protective ileostomy.

The patient had a satisfactory immediate postoperative course, without complications, and remained hospitalized for seven days. She was discharged in good general condition with scheduled outpatient follow-up, showing resolution of the episodes of hematochezia and significant clinical improvement.

Four months later, intestinal continuity was restored by ileostomy reversal, with no complications.

During late outpatient follow-up, significant improvement in the bleeding condition and normalization of hematimetric parameters were observed. The patient reported only sporadic episodes of minor bleeding, attributed to residual lesions in the anal canal and residual rectum (Figure 5).

She therefore underwent excision of the residual venous lesions associated with local cauterization, with marked symptom improvement and a positive, significant impact on quality of life.

She currently remains under outpatient follow-up, without the need for continuous medication and with no further relevant episodes of lower gastrointestinal bleeding.

Figure 1 — Intraoperative colonoscopy.

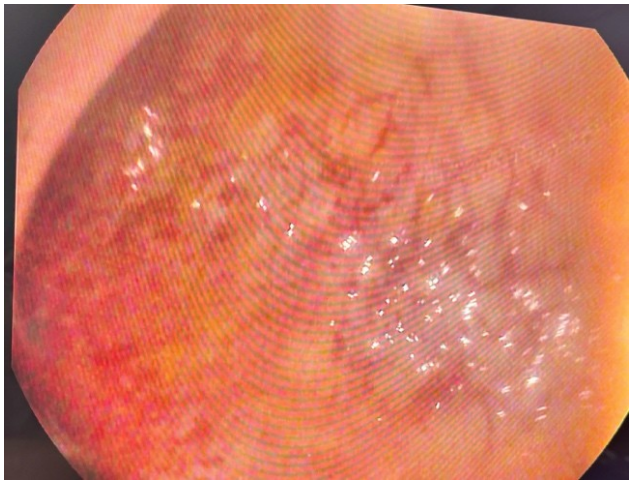

Figure 1. Colonoscopy showing diffuse vascular involvement of the rectum and sigmoid colon, characterized by ectatic, violaceous vessels and friable mucosa compatible with cavernous colorectal hemangioma.

Figure 2 — Intraoperative colonoscopy.

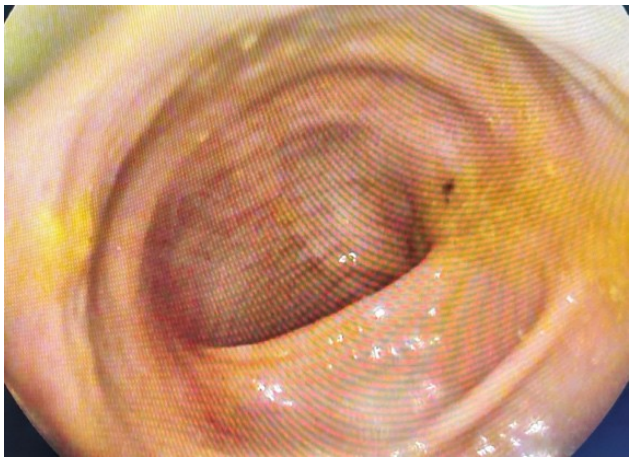

Figure 2. Colonoscopy showing normal mucosa in contrast with the previous image.

Figure 3 — Intraoperative laparoscopy.

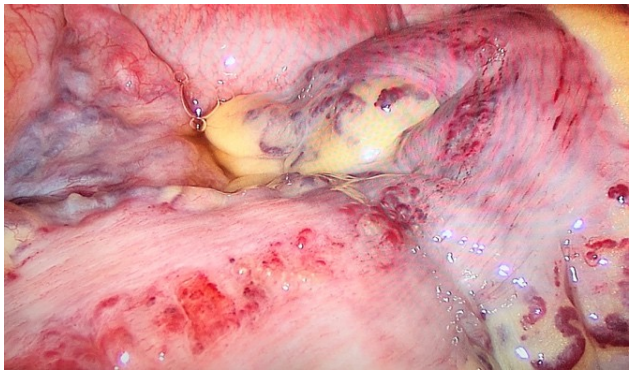

Figure 3. Laparoscopic image showing ectatic, violaceous subserosal vessels.

RCMOS – Revista Científica Multidisciplinar O
Saber. ISSN: 2675-9128. São Paulo - SP.
Ano VII, v.1 2026 | submissão: 23/07/2026 | aceito: 26/07/2026 | publicação: 29/07/2026

Figure 4 — Intraoperative laparoscopy.

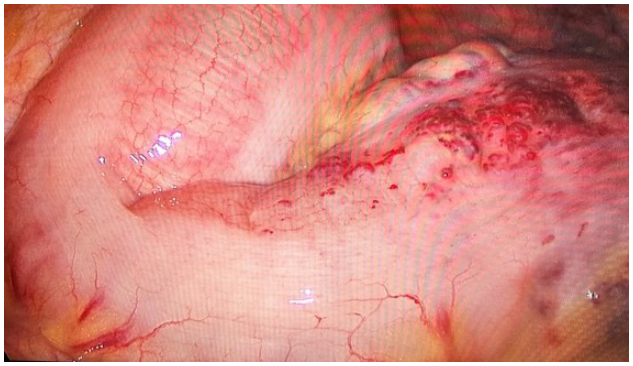

Figure 4. Laparoscopic image showing areas with vascular lesions and areas without abnormalities.

Figure 5 — Anoscopy.

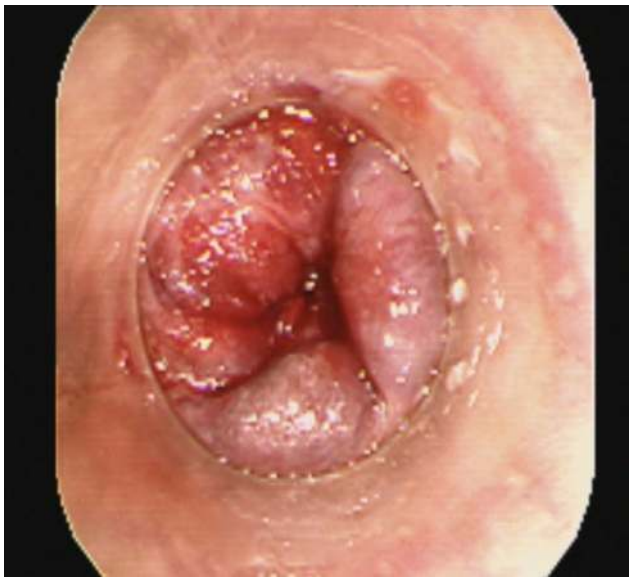

Figure 5. Anoscopy showing purplish-erythematous, friable angiectasias in the anal canal, with areas of vascular congestion. The adjacent mucosa had a congested appearance, with no evidence of other abnormalities.

RCMOS – Revista Científica Multidisciplinar O
Saber. ISSN: 2675-9128. São Paulo - SP.
Ano VII, v.1 2026 | submissão: 23/07/2026 | aceito: 26/07/2026 | publicação: 29/07/2026

Figure 6 — Surgical specimen.



Figure 6. Surgical specimen consisting of a segment of the rectum and sigmoid colon measuring approximately 20 cm, with diffuse vascular involvement of the intestinal wall characterized by multiple ectatic, violaceous vessels, predominantly in the rectum and distal sigmoid colon.

Discussion

Colorectal hemangiomas are rare vascular lesions, generally congenital in origin, and the cavernous subtype is the most frequently described[1,3]. Diffuse involvement of the rectum and sigmoid colon is the most common form of presentation[2].

The main clinical manifestation is recurrent hematochezia, frequently associated with chronic iron deficiency anemia[4]. Diagnosis is usually delayed, mainly because of low clinical suspicion and similarity to more prevalent diseases, including hemorrhoidal disease and inflammatory bowel diseases[2,5].

In the case presented, the patient remained under treatment for ulcerative colitis for years without an adequate clinical response, demonstrating a major diagnostic challenge. The absence of clinical improvement associated with persistent lower gastrointestinal bleeding should prompt diagnostic reassessment and investigation of less frequent causes[5].

Colonoscopy is a fundamental tool for diagnostic suspicion[6], allowing visualization of violaceous, friable submucosal vascular lesions that bleed easily. However, because of the hemorrhagic risk, biopsies should be performed judiciously[4].

In extensive cases or those associated with persistent bleeding, surgical treatment remains the therapeutic modality of choice[1,2]. The laparoscopic approach offers advantages related to lower postoperative morbidity, less pain, faster recovery, and better functional outcomes.

In this case, the use of intraoperative colonoscopy was fundamental for adequately delimiting the affected margins, enabling precise planning of intestinal resection and sphincter preservation.

The favorable clinical course observed after surgical treatment demonstrates the effectiveness of the approach adopted, with significant resolution of gastrointestinal bleeding, hematimetric recovery, and a major improvement in quality of life.

Conclusion

The hemangioma proved challenging until the correct diagnosis was reached, particularly because of the rarity of its presentation, its similarity to other colorectal disorders, and the absence of specific clinical findings.

Persistent recurrent hematochezia associated with iron deficiency anemia, especially in patients who do not respond to conventional treatment for inflammatory bowel disease, should raise suspicion of colorectal vascular malformations.

Laparoscopic surgical treatment combined with adequate intraoperative delimitation of the disease proved safe and effective, providing significant clinical improvement and a positive impact on the patient's quality of life.

Conflict of Interest

The authors declare that there are no conflicts of interest.

Funding

The authors declare that there were no sources of funding.

References

Wang HT, Gao XH, Fu CG, Wang ZJ. Diffuse cavernous hemangioma of the rectum: report of 17 cases. World J Surg. 2010;34(10):2477-86.

Jain BK, Chandra SS, Narasimhan R, Ananthakrishnan N, Mehta RB. Diffuse cavernous hemangioma of the rectum: report of two cases and review of literature. World J Gastroenterol. 2005;11(47):7548-51.

Gentry RW, Dockerty MB, Clagett OT. Vascular malformations and vascular tumors of the gastrointestinal tract. Surg Gynecol Obstet. 1949;88(3):281-323.

Barksdale EM Jr, Obokhare I. Cavernous hemangioma of the rectosigmoid colon: a rare cause of lower gastrointestinal bleeding. Am Surg. 2009;75(10):1002-4.

Ksiadzyna D. Diffuse cavernous hemangioma of the rectum: diagnosis and management. World J Gastroenterol. 2015;21(18):5542-5.

Ano VII, v.1 2026 | submissão: 23/07/2026 | aceito: 26/07/2026 | publicação: 29/07/2026

Ruiz Casado A, Martínez Burgui J, López Marcano A, et al. Diffuse cavernous hemangioma of the rectum: MRI diagnosis and surgical management. Rev Esp Enferm Dig. 2011;103(12):629-31.