Machine Translated by Google
RCMOS - Multidisciplinary Scientific Journal The Knowledge.
ISSN: 2675-9128. São Paulo-SP.

Year VI, v.1 2026 | Submission: 03/21/2026 | Accepted: 03/23/2026 | Publication: 03/25/2026 **Conservative Surgical-Endodontic Treatment of an Extensive Inflammatory Periapical Cyst in the Maxilla: A Clinical Case Report**

Conservative Surgical-Endodontic Management Of An Extensive Inflammatory Periapical Cyst In The Maxilla: A Clinical Case Report

Cláudio Maranhão Pereira – Pontifical Catholic University of Goiás.
Email: claudiopereira@pucgoias.edu.br

Gustavo Rocha Vita – Pontifical Catholic University of Goiás.
Email: gustavo.vita@pucgoias.edu.br

Guilherme Ribeiro de Queiroz – Pontifical Catholic University of Goiás.
Email: guilherme.queiroz@pucgoias.edu.br

Daniel Sousa Santos – Pontifical Catholic University of Goiás.
Email: danielss12.ds@gmail.com

Heitor Lima Ribeiro – Pontifical Catholic University of Goiás.
Email: heitorlimaribeiro@gmail.com

Summary

Inflammatory periapical cysts are the most prevalent odontogenic cystic lesions, originating from the proliferation of epithelial rests of Malassez in response to chronic pulp necrosis. Large cases, with bilateral cortical destruction and involvement of multiple teeth, represent a significant diagnostic and therapeutic challenge. The aim of this study is to describe the diagnostic and therapeutic approach employed in a case of extensive periapical cyst in the anterior maxilla, involving seven teeth and destruction of the vestibular and palatal cortical bone. This is a clinical case report of a 27-year-old female patient with a lesion involving the apices of teeth 11, 12, 13, 21, 22, 23, and 24, with destruction of the vestibular and palatal cortical bone and bilateral communication confirmed by cone-beam computed tomography. The treatment consisted of endodontic therapy of the teeth with pulp necrosis, followed by surgical enucleation of the lesion with curettage of the bone walls and apicoectomy of the affected teeth, under general anesthesia in a hospital setting.

In the 24-month clinical and radiographic follow-up, favorable evolution was observed, with no clinical recurrence and maintenance of preserved dental elements. It is concluded that the multimodal conservative approach, combining endodontic treatment and periapical surgery, proved effective in managing the case, with correct diagnosis, multidisciplinary planning, and periodic follow-up being decisive for the therapeutic outcome.

Keywords: periapical cyst; endodontic treatment; enucleation; apicoectomy; oral pathology.

Abstract

The inflammatory periapical cyst is the most prevalent odontogenic cystic lesion and arises from the proliferation of epithelial remnants of Malassez in response to chronic pulp necrosis. Extensive cases with bilateral cortical destruction and involvement of multiple teeth represent an important diagnostic and therapeutic challenge. This study aims to describe the diagnostic and therapeutic approach employed in a case of an extensive periapical cyst in the anterior maxilla involving seven teeth and destruction of the buccal and palatal cortical plates. This is a clinical case report of a 27-year-old female patient presenting a lesion involving the apices of teeth 11, 12, 13, 21, 22, 23 and 24, with destruction of the buccal and palatal cortical plates and bilateral communication confirmed by cone-beam computed tomography. Treatment consisted of endodontic therapy of teeth with pulp necrosis, followed by surgical enucleation of the lesion with curettage of the bony walls and apicoectomy of the affected teeth under general anesthesia in a hospital setting. During 24 months of clinical and radiographic follow-up, favorable evolution, absence of clinical recurrence and preservation of the involved teeth

This is an open access article published under the Creative Commons Attribution license, which permits unrestricted use, distribution, and reproduction in any medium, provided the original work is properly cited.

Machine Translated by Google

Year VI, v.1 2026 | submission: 03/21/2026 | accepted: 03/23/2026 | publication: 03/25/2026 were observed. It is concluded that the conservative multimodal approach, combining endodontic treatment and periapical surgery, proved effective in the management of the case, and that accurate diagnosis, multidisciplinary planning and periodic follow-up were decisive for the therapeutic outcome.

Keywords: periapical cyst; endodontic treatment; enucleation; apicoectomy; oral pathology.

1. Introduction

An inflammatory periapical cyst, also called a radicular cyst or apical cyst, represents... the most prevalent odontogenic cystic lesion of the oral cavity, corresponding to a significant portion of the cysts diagnosed in routine stomatological and anatomopathological examinations. Their etiopathogenesis is related to chronic infection of the root canal system, which triggers the proliferation of epithelial rests of Malassez present in the periodontal ligament, culminating in the formation of pathological cavity lined by epithelium (NEVILLE et al., 2016; SANTOSH, 2020).

The expansion of the lesion results from the maintenance of the inflammatory stimulus and the elevation of pressure. Intraluminal osmotic pressure, associated with the accumulation of cellular debris and bacterial products. In general, the Growth occurs slowly and silently, which is why many cases are identified. incidentally in imaging exams requested for other reasons (NAIR, 2006; OSORIO et al., 2023).

From an epidemiological point of view, periapical cysts predominantly affect adults. young and middle-aged people, with a relative predilection for the anterior region of the maxilla. Although most Even in cases where it is asymptomatic, large lesions can cause cortical bulging. Tooth mobility, root displacement, local discomfort and, in more aggressive presentations, loss of vestibular and palatal bone structure (SANTOSH, 2020; IMMANUEL; PANDIAR; KRISHNAN, 2024).

Proper diagnosis requires integration between medical history, physical examination, and tests. Pulp sensitivity, imaging studies, and histopathological confirmation. In the context of lesions In extensive cases, cone beam computed tomography plays a strategic role, as it allows for evaluation. three-dimensional extent, cortical integrity, and relationship to adjacent anatomical structures, providing more reliable subsidies for surgical planning (PATEL et al., 2019).

Histopathologically, periapical cysts are generally characterized by the presence of epithelium. non-keratinized stratified squamous cell carcinoma associated with loose connective tissue with infiltrate Chronic inflammation of varying intensity, areas of old bleeding, cholesterol crystals, and Eventually, Rushton bodies. Microscopic confirmation is crucial to rule out other possibilities. Diagnostic hypotheses for periapical radiolucent lesions (CAWSON; ODELL, 2017).

Regarding treatment, the literature supports the elimination of the etiological factor through... Endodontic therapy is essential. However, in extensive lesions, especially those with... In cases of significant cortical destruction and involvement of multiple teeth, combined therapy is indicated.

This is an open access article published under the Creative Commons Attribution license, which permits unrestricted use, distribution, and reproduction in any medium, provided the original work is properly cited.

Machine Translated by Google

Year VI, v.1 2026 | Submission: 03/21/2026 | Accepted: 03/23/2026 | Publication: 03/25/2026

Endodontic approach and surgical intervention tend to be the most predictable course of action, whether due to Enucleation, marsupialization, or a combination of techniques, depending on the characteristics of the case (KARAMIFAR et al., 2020; PESÁNTEZ ALVARADO; LAFEBRE CARRASCO, 2025).

Given this context, this study aims to report a clinical case of a periapical cyst. Extensive inflammation in the anterior region of the maxilla, involving seven teeth and destruction. bilateral cortical bone lesions, describing the diagnostic sequence, multidisciplinary planning and The therapeutic protocol adopted emphasizes a conservative approach focused on preservation. dental.

2. Material and Method

This is a descriptive, qualitative, retrospective study, of the clinical case report type. developed from the analysis of clinical, radiographic, tomographic, surgical and data Histopathological examinations of a patient treated at a university stomatology service and subsequently referred for hospital treatment.

The following data were considered for the composition of the report: anamnesis, extraoral physical examination, and intraoral, pulp vitality tests, aspiration puncture, two-dimensional imaging exams and three-dimensional, histopathological report, information regarding endodontic therapy, to surgical procedure and postoperative clinical and radiographic follow-up.

The case was documented for academic and scientific purposes, while preserving the anonymity of the individual. of the patient at all stages. Authorization was given for the use of clinical data, images and information relevant to the report, in accordance with ethical principles applicable to the publication of clinical cases.

The analysis and discussion of the case were conducted in light of the relevant scientific literature, with Emphasis on etiopathogenic aspects, diagnostic criteria, therapeutic indication, and prognosis of extensive inflammatory periapical cysts.

3. Results and discussion

A 27-year-old female patient, of mixed race, with no relevant systemic comorbidities, presented to the Stomatology Clinic of the Faculty of Dentistry with a chief complaint of pain in tooth 22. According to her report, she had received previous care at a Basic Health Unit and, given the complexity of the condition, was referred to the university service for diagnostic investigation and treatment.

On extraoral physical examination, no noteworthy alterations were observed. On intraoral examination, discoloration of teeth 11, 12, 21, and 22 was evident, as well as palatal mobility of tooth 22, slight bulging in the left anterior region of the maxilla on the vestibular side, and increased volume in the hard palate region (Figures 1 and 2).

This is an open access article published under the Creative Commons Attribution license, which permits unrestricted use, distribution, and reproduction in any medium, provided the original work is properly cited.

Machine Translated by Google
RCMOS - Multidisciplinary Scientific Journal The Knowledge.
ISSN: 2675-9128. São Paulo-SP.

Year VI, v.1 2026 | Submission: 03/21/2026 | Accepted: 03/23/2026 | Publication: 03/25/2026 Figure 1 – Frontal view of the oral cavity showing color alteration of elements 11, 12, 21 and 22.



Source: authors' archive.

Figure 2 – Increased volume in the hard palate region.

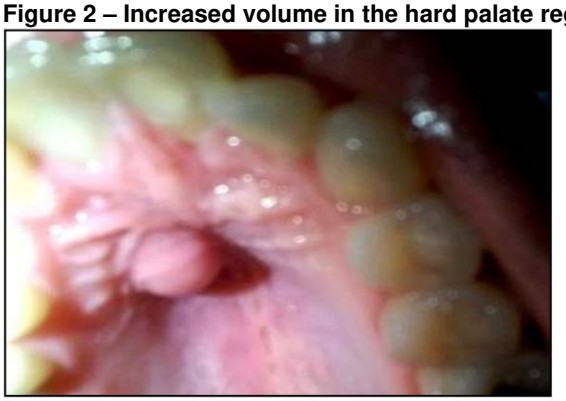

Source: authors' archive.

Imaging tests were requested to assess the extent of the injury. X-ray
The panoramic image revealed a radiolucent, unilocular image, relatively well delimited by a halo.
thin radiopaque lesion, involving the apices of teeth 11, 12, 13, 21, 22, 23 and 24 (Figure 3).

Figure 3 – Initial panoramic radiograph showing an extensive unilocular radiolucent lesion in the anterior maxilla.

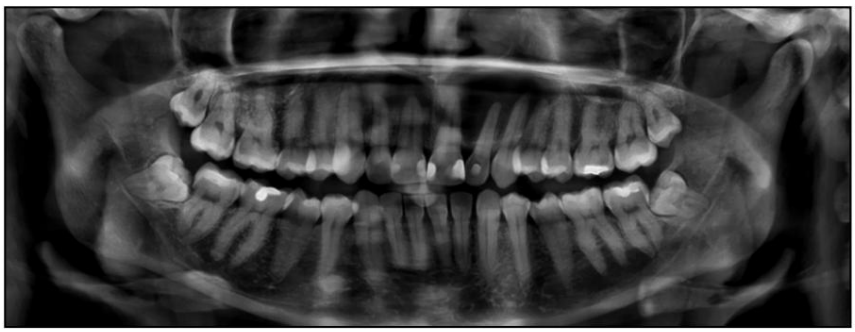

Source: authors' archive.

Cone beam computed tomography showed a hypodense, homogeneous image.
unilocular, with well-defined borders, encompassing the apices of teeth 11 and 12, extending to the root.
of element 13, on the right, and the apices of elements 21, 22, 23, and 24, on the left. The evaluation
Three-dimensional imaging revealed complete destruction of the vestibular and palatal cortical bone, in addition to
communication between the right and left sides of the maxilla, characterizing a lesion of large

This is an open access article published under the Creative Commons Attribution license, which permits unrestricted use, distribution, and reproduction in any medium, provided the original work is properly cited.

Machine Translated by Google
RCMOS – Multidisciplinary Scientific Journal The Knowledge.
ISSN: 2675-9128. São Paulo-SP.

Year VI, v.1 2026 | Submission: 03/21/2026 | Accepted: 03/23/2026 | Publication: 03/25/2026

proportions (Figures 4, 5 and 6).

Figure 4 – Cone beam computed tomography in panoramic reconstruction, showing the extent of the lesion.

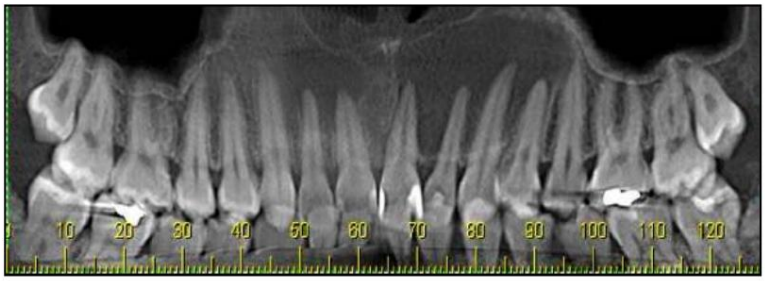

Source: authors' archive.

Figure 5 – Three-dimensional reconstruction of the left side, showing cortical bone loss.



Source: authors' archive.

Figure 6 – Axial tomographic slices, from superior to inferior, confirming bilateral communication and disruption of the vestibular and palatal cortices.

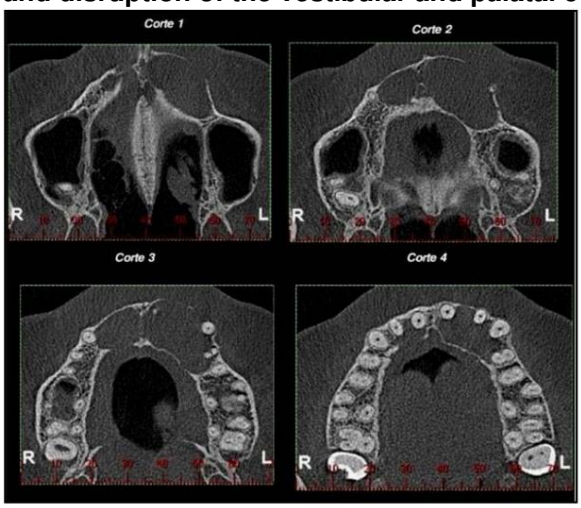

Source: authors' archive.

CBCT was crucial for surgical planning, as it provided information that goes beyond...
the diagnostic capability of two-dimensional radiography, especially regarding the actual dimensions of
The finding is a pathological cavity, cortical bone loss, and bilateral communication.
consistent with the literature, which highlights the superiority of CBCT in the evaluation of periapical lesions.
extensive and in defining surgical risk and surgical access (PATEL et al., 2019).

Cold pulp vitality tests showed a positive response in teeth 13, 23, and 24.
and a negative response in elements 11, 12, 21, and 22, confirming pulp necrosis in the latter. A
Aspiration biopsy resulted in the collection of a yellow-citrine fluid, with a suggestive bright appearance.

This is an open access article published under the Creative Commons Attribution license, which permits unrestricted use, distribution, and reproduction in any medium, provided the original work is properly cited.

Machine Translated by Google

Year VI, v.1 2026 | submission: 03/21/2026 | accepted: 03/23/2026 | publication: 03/25/2026 of cholesterol crystals, followed by blood, reinforcing the hypothesis of inflammatory cystic lesion.

Fine-needle aspiration, while not a substitute for histopathology, has proven relevant as an examination. complementary in diagnostic reasoning, since the aspect of the aspirated content is classically associated with inflammatory odontogenic cystic lesions. In extensive radiolucent lesions, this step It also helps rule out vascular malformations and reduces the risk of complications. intraoperative.

An incisional biopsy of the lesion was performed through an incision above tooth 22, with mucoperiosteal detachment (Figure 7). The previous destruction of the vestibular cortex made the procedure unnecessary. The need for osteotomy for initial access. The material obtained was fixed in buffered formalin. 10% and sent for anatomopathological analysis. The histopathological examination demonstrated Lining by non-keratinized stratified squamous epithelium, associated with connective tissue stroma. loose, chronic inflammatory infiltrate, cholesterol crystals and hemosiderin, consistent with a cyst. inflammatory periapical lesion.

Figure 7 – Initial surgical approach for incisional biopsy of the lesion.



Source: authors' archive.

The microscopic pattern found was consistent with the classic description of periapical cysts. inflammatory, consolidating the diagnostic hypothesis put forward based on the clinical presentation and tests of image. This diagnostic chain was important because radiolucent periapical lesions Extensive lesions require differentiation from periapical granulomas, odontogenic keratocysts, unicystic ameloblastomas and other osteolytic changes of the jaws (CAWSON; ODELL, 2017; KARAMIFAR et al., 2020).

Given the extent of the injury, a combined therapeutic approach was chosen. Elements 11, Patients 12, 21, and 22 underwent endodontic therapy due to pulp necrosis. The preparation Biomechanical analysis was performed using Flexofile K-type files under irrigation with 2.5% sodium hypochlorite. Due to the presence of abundant purulent exudate, an indwelling intracanal medication was used. with formocresol in a 1:5 dilution, with bi-weekly changes for two months, associated with Systemic antibiotic therapy with amoxicillin and metronidazole. After resolution of the infectious condition, The canals were obturated using a lateral condensation technique with resin cement (Figure 7).

This is an open access article published under the Creative Commons Attribution license, which permits unrestricted use, distribution, and reproduction in any medium, provided the original work is properly cited.

Machine Translated by Google
RCMOS – Multidisciplinary Scientific Journal The Knowledge.
ISSN: 2675-9128. São Paulo-SP.

Year VI, v.1 2026 | submission: 03/21/2026 | accepted: 03/23/2026 | publication: 03/25/2026 Figure 7 – Periapical radiograph of teeth 11, 12, 21 and 22 after endodontic obturation.



Source: authors' archive.

Although the use of formocresol is now subject to greater restriction and debate, due to issues related to cytotoxicity and the availability of more biocompatible options, the control of Exudate control and stabilization of the infectious condition were achieved in this case. The literature Contemporary medicine, however, tends to favor intracanal medications such as calcium hydroxide in similar contexts, due to their better biological profile and their contribution to disinfection of canal system and for tissue repair (ESTRELA, 2018). This point deserves to be recognized. critically, without, however, invalidating the clinical result achieved.

After the endodontic treatment was completed, the patient was referred to the hospital for surgical treatment. under general anesthesia. In the preoperative assessment, she was in good general condition, oriented, without Signs of systemic compromise. The procedure was performed under nasotracheal intubation, with supplemental local anesthesia.

An intrasulcular incision was made from tooth 16 to 26, followed by dissection. Extensive mucoperiosteal access. Bilateral surgical bone windows were created for access to Cystic cavity. Complete enucleation of the lesion was performed, followed by meticulous curettage of the walls. The bony prominences were then thoroughly irrigated with a 0.9% saline solution. Following this, an apicoectomy of the... The elements involved were treated with beveled root resection. The flap was repositioned and sutured. (Figure 8).

Figure 8 – Bilateral surgical bone window for access to the lesion.



Source: authors' archive.

This is an open access article published under the Creative Commons Attribution license, which permits unrestricted use, distribution, and reproduction in any medium, provided the original work is properly cited.

Machine Translated by Google

Year VI, v.1 2026 | Submission: 03/21/2026 | Accepted: 03/23/2026 | Publication: 03/25/2026

The choice to perform enucleation was consistent with the magnitude of the lesion and the need for... Complete removal of the pathological capsule also facilitates a thorough histopathological examination. Marsupialization could be considered in other contexts, especially when there is a higher risk. surgical, critical proximity to important anatomical structures, or need for decompression. progressive. In this case, however, the patient's good general condition, favorable access, and hospital planning supported the choice for complete removal (PESÁNTEZ ALVARADO; LAFEBRE CARRASCO, 2025; DOUMARI et al., 2025).

Apicoectomy of the affected elements was part of the conservative approach to preserving the teeth, seeking to eliminate potentially contaminated apical areas and reduce the chance of persistence of the pathological process. In extensive cases, especially when the lesion involves Multiple apices and significant bone destruction, associated with previous endodontic treatment. and parendodontic surgery can increase therapeutic predictability.

On the first postoperative day, the patient was in good general condition and without pain. Important, with no active bleeding and tolerating an oral diet. Discharged from the hospital with a prescription. medication, hygiene instructions, and post-operative care.

At the one-week follow-up, the patient showed satisfactory progress, with no signs of infection. dehiscence or local complications. The panoramic radiograph is performed approximately two Weeks after the procedure, the previously radiolucent area became cloudy. compatible with the initial phase of clot organization and the beginning of the repair process.

It's important not to overinterpret this initial image. Radiographically, two weeks is not... sufficient to confirm consolidated bone repair. The real value of the case lies in the clinical follow-up. Serial radiographic examination. At 24 months, the patient remained asymptomatic, with no clinical signs of Relapse, with preservation of the dental elements and compatible radiographic evolution. with progressive repair.

This prolonged follow-up substantially strengthens the report. Many published cases They fail because they only present immediate or short-term postoperative data, which weakens the conclusion. Regarding therapeutic stability, here, monitoring for 24 months makes the outcome more robust. especially given the large initial extent of the injury.

The prognosis for periapical cysts treated appropriately tends to be favorable, provided that There must be elimination of the causal factor, appropriate removal of the lesion capsule, and periodic follow-up. In extensive cases, bone neoformation may be slow, and long-term monitoring is necessary. indispensable for confirming stability and ruling out recurrence (NEVILLE et al., 2016; IMMANUEL; PANDIAR; KRISHNAN, 2024).

As an inherent limitation of this report, it is acknowledged that generalizations are impossible. results and the absence, in this manuscript, of late tomography documenting bone remodeling

This is an open access article published under the Creative Commons Attribution license, which permits unrestricted use, distribution, and reproduction in any medium, provided the original work is properly cited.

Machine Translated by Google

Year VI, v.1 2026 | submission: 03/21/2026 | accepted: 03/23/2026 | publication: 03/25/2026

final. Still, the combination of serial clinical evaluation, radiographic documentation and
A 24-month follow-up provides sufficient consistency to the observed outcome.

Figure 9 – Postoperative panoramic radiograph, approximately 4 months after surgery, suggesting the initial phase of bone repair.

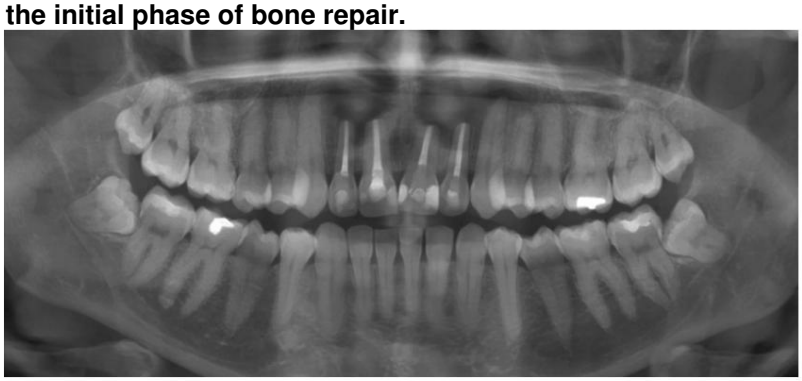

Source: authors' archive.

4 final considerations

This report demonstrates that the inflammatory periapical cyst, even when it presents as
In its extensive form, with bilateral destruction of cortical bone and involvement of multiple teeth, it can...
to be managed conservatively, with tooth preservation, provided the diagnosis is
properly established and the therapeutic plan is individualized.

In the case presented, the association between endodontic treatment, surgical enucleation,
Curettage and apicoectomy, performed in a hospital setting under general anesthesia, resulted in evolution.
Favorable clinical and radiographic results during 24 months of follow-up, with no clinical recurrence.
detectable.

This case reinforces the importance of integration between stomatology, endodontics, and surgery.
Oral and maxillofacial surgery, imaging, and pathological anatomy in the safe management of extensive lesions of the anterior maxilla.

Financing

The authors declare that there was no funding for this study.

Conflict of interest

The authors declare no conflict of interest.

Ethical aspects

The patient authorized the use of clinical, radiographic, and photographic data for academic purposes.
and scientific, while preserving their identity. The procedures described followed the principles
Ethical guidelines applicable to the publication of case reports.

This is an open access article published under the Creative Commons Attribution license, which permits unrestricted use, distribution, and reproduction in any medium, provided the original work is properly cited.

Machine Translated by Google

Year VI, v.1 2026 | Submission: 03/21/2026 | Accepted: 03/23/2026 | Publication: 03/25/2026 References

CAWSON, RA; ODELL, EW *Cawson's essentials of oral pathology and oral medicine.* 9. ed. Edinburgh: Elsevier, 2017.

DOUMARI, B. et al. Post-traumatic radicular cyst involving multiple anterior teeth: open apex management and surgical enucleation – a case report. *Advances in Oral and Maxillofacial Surgery,* [sl], v. 19, p. 100558, 2025.

ESTRELA, C. *Endodontics: science and technology.* 3rd ed. São Paulo: Artes Médicas, 2018.

IMMANUEL, SA; PANDIAR, D.; KRISHNAN, RP Periapical cysts – a comprehensive review. *Journal of Oral and Maxillofacial Pathology,* [sl], v. 28, no. 1, p. 149-159, 2024.

KARAMIFAR, K. et al. Endodontic periapical lesion: an overview on the etiology, diagnosis and current treatment modalities. *Journal of Clinical and Experimental Dentistry,* [sl], v. 12, no. 7, p. e686-e693, 2020.

NAIR, PNR On the causes of persistent apical periodontitis: a review. *International Endodontic Journal,* [sl], v. 39, no. 4, p. 249-281, 2006.

NEVILLE, BW et al. *Oral and maxillofacial pathology.* 4th ed. St. Louis: Elsevier, 2016.

OSORIO, NR et al. The paradigm of the inflammatory radicular cyst: biological aspects to be considered. *European Endodontic Journal,* [sl], v. 8, no. 1, p. 20-36, 2023.

PATEL, S. et al. Cone beam computed tomography in Endodontics – a review of the literature. *International Endodontic Journal,* [sl], v. 52, no. 8, p. 1138-1152, 2019.

PESÁNTEZ ALVARADO, JM; LAFEBRE CARRASCO, MF A radicular cyst with extensive bone loss requires surgical and endodontic management: case presentation and literature review. *Case Reports in Dentistry,* [sl], 2025.

SANTOSH, ABR Odontogenic cysts. *Dental Clinics of North America,* [sl], v. 64, no. 1, p. 105-119, 2020.

This is an open access article published under the Creative Commons Attribution license, which permits unrestricted use, distribution, and reproduction in any medium, provided the original work is properly cited.