Translated from Portuguese to English - www.onlinedoctranslator.com

RCMOS – Multidisciplinary Scientific Journal O Saber.
ISSN: 2675-9128. Sao Paulo-SP.

Dental treatment in a surgical center in a patient with hyaline fibromatosis: clinical case report

Dental treatment in the operating room in a patient with hyaline fibromatosis: clinical case report

Jéssica Sabrina Farias Brazil
Dr. Alberto Consolaro
Luciana Cristina Grisoto
Caio Vinicius Gonçalves Roman Torres
Sérgio TakashiKussaba

Submitted on: 06/25/2022
Approved on: 06/26/2022 Published on: 06/28/2022
DOI: 10.51473/rcmos.v2i1.320

1. INTRODUCTION

Juvenile hyaline fibromatosis (JHF) is a rare hereditary disease, with an autosomal recessive character and unknown etiology. The onset of clinical manifestations of JHF is typically three to four months of age.**(**Al-Najjadah I, et al., 2003), and mental development is normal (Al-Najjadah I, et al., 2003**,**Muniz ML, et al., 2006).

In juvenile hyaline fibromatosis, the lesions can be pearly papules on the face, neck and especially in the retroauricular and perinasal regions, large tumors, mainly on the scalp, trunk, limbs, plaques or perianal nodules, and gingival hypertrophy is common, impairing nutrition. (Al-Najjadah I, et al., 2003, Ramos AMCR, 1994). Gingival hypertrophy is a common finding and can be severe enough to interfere with correct eating and eventually chewing, which in turn can lead to malnutrition, recurrent infections and even death (KESER et al., 1999, LARRALDE et al., 2001).

Bone manifestations include osteolytic lesions, mainly in the phalanges and distal metaphyses, cortical thinning and generalized osteopenia.**(**Al-Najjadah I, et al., 2003, Ramos AMCR, 1994). There are reports of scoliosis, macrocephaly and reduced weight and height**(**Al-Najjadah I, et al., 2003**,**Muniz ML, et al., 2006). There are few cases reported in the literature, until 2007 only 70 cases were reported (Uslu*et al.,*2007).

The gene that causes FHJ was mapped to the 7-cM interval on chromosome 4q21, and it was recently identified that this genetic error causes a deficit in hair morphogenesis protein 2 (CMG2) (RAHMAN*et al.,*2002; HAKKI*et al.,*2005). The CMG2 protein is a regulator of endothelial cells during the period of capillary morphogenesis, with a strong connection with the lamina and type IV collagen (DOWLING*et al.,*2003; AGHIGHI*et al.,*2005).

The deposition of amorphous hyaline material of glycoprotein constitution in the skin, mucous membranes and internal organs appears to be related to an alteration in collagen synthesis and metabolism, leading to an increase in the production of collagen types IV and V by the endothelial cells of blood vessels, and increased synthesis of a glycoprotein substance by fibroblasts (LIMA*et al.,*2003; ISHIKAWA*et al.,*1979; HANKS*et al.,*2003). It is known, however, that the increase in collagen IV is mainly responsible for the joint stiffness present in this pathology, and the deposition of hyaline in the digestive tract, caused by enteropathy. (Raeeskarami SR, et al., 2014). The prognosis in FHJ (juvenile hyaline fibromatosis) is very variable and depends on the age of onset of symptoms and the degree of joint involvement (Yoo SY, et al., 2010) Average life expectancy is 20-30 years (Lindvall LE , et al., 2008).

Treatment of these lesions consists of surgical excision. However, this practice can be disabling and recurrences are frequent.**(**Al-Najjadah I, et al., 2003**,**Muniz ML, et al., 2006**,**Ramos AMCR, 1994). Regarding gingival hypertrophy, injections with proteolytic enzymes are still being tested (Cam B, et al., 2015), but treatment involves partial gingivectomy, although new growth occurs after some time. There is no specific treatment for hyalinosis, and the main objective of the approach taken to these patients is to improve quality of life and treat pain. Other therapeutic measures that probably have a greater impact on the quality of life of these patients include physiotherapy, adequate nutritional support and analgesia with non-steroidal anti-inflammatory drugs.

and opioids (Jaouad IC, et al., 2014).

Therefore, the objective of this work will be to clinically describe a case of FHJ and verify the quality of life and functionalities of an affected patient, after dental treatment in a surgical center.

2 CLINICAL CASE

EFG, female, white, three years old, diagnosed with Hyaline Fibromatosis, and functional dependence to carry out her daily activities. He attended the outpatient clinic of the specialized dentistry clinic at Hospital da Criança Santo Antônio (HCSA/Boa Vista/RR), presenting with extensive gingival hyperplasia,

This is an article published in Open Access under the CreativeCommons Attribution license, which permits unrestricted use, distribution and reproduction in any medium, as long as the original work is correctly cited.

compromising the alveolar region and upper lip (Figure 1 and 2), joint contractures of upper and lower limbs, assuming a supine position and growth retardation. No apparent impairment of mental development. Laboratory tests were within normal limits and the biopsy of two of the nodules showed hyaline, amorphous and eosinophilic material.

After requesting pre-anesthetic evaluation, due to the patient's condition with limited mouth opening, it was not possible to perform orotracheal intubation, it was necessary to use fibroscopy for her intubation. (Figure 3). Gingival hyperplasia excision surgery was performed with electrocautery.



Figure 1. Source: From the authors (2022).



Figure 2. Source: From the authors (2022).

This is an article published in Open Access under the CreativeCommons Attribution license, which permits unrestricted use, distribution and reproduction in any medium, as long as the original work is correctly cited.



Figure 3. Source: From the authors (2022).

The dental treatment was carried out in the surgical center of the children's hospital, and after the procedure, guidance on oral and dental hygiene was given to their caregivers. The patient is currently undergoing multidisciplinary monitoring at the dental specialty center, with regular returns every three months for maintenance and control.



Immediate result. (Figure 4). Source: From the authors (2022).



Result after one week. (Figure 5). Source: From the authors (2022).

This is an article published in Open Access under the CreativeCommons Attribution license, which permits unrestricted use, distribution and reproduction in any medium, as long as the original work is correctly cited.

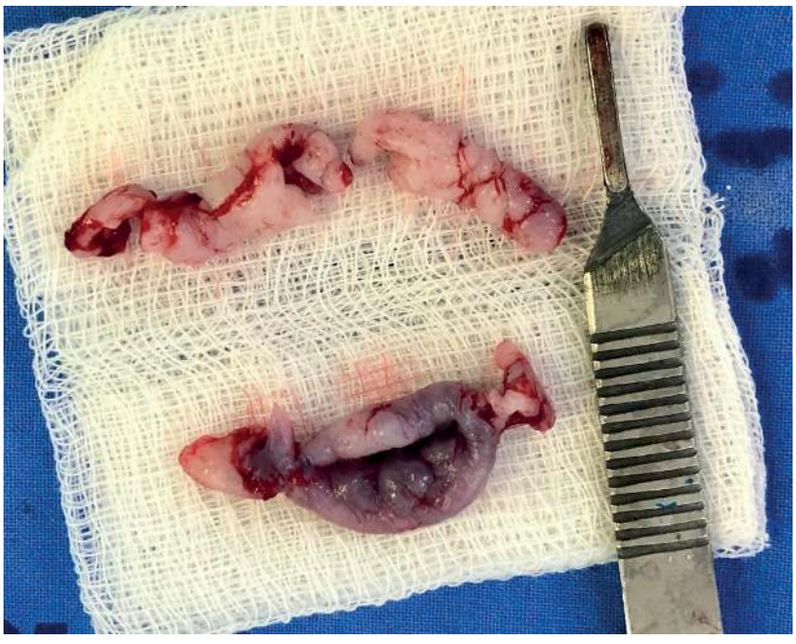

Fabric sample. (Figure 6). Source: From the authors (2022).

3 DISCUSSION

Gingival hyperplasia is common in most cases of juvenile hyaline fibromatosis; in fact, it is rarely absent. Increased gingival volume can lead to tooth displacement; retention of deciduous teeth; appearance of diastemas; phonetic difficulties; when chewing; delay in tooth eruption; and greater propensity for caries lesions and periodontal disease, due to the great difficulty of cleaning. Therefore, FGH treatment must be focused on aesthetic and functional restoration, combined with good oral health conditions (Serra et al., 2007; Harris et al., 2012; Aghili & Moghadam, 2013).

According to Kharbanda et al., (1993) in radical treatment that consists of the total removal of teeth, relapse does not occur. In conservative treatment, that is, gingivectomies and gingivoplasties, recurrence is common and occurs at different periods.

According to Regezzi & Sciubba (1991), these lesions do not have the potential for malignant transformation, and simple surgical excision is effective. Surgical treatment consists of gingivectomy, with or without apical flap repositioning, together with a rigorous oral hygiene program. Association of selective tooth extraction in severe cases may be necessary to obtain a normal tissue morphology of the gums and serve as a means of controlling gingival growth, since, according to the authors, the gingival growth mechanism gives way in the absence of teeth, due to a reason not yet identified (Carranza; Newman, 1987).

In the histopathology of this case, the appearance of surface epithelium was found, presenting an intense chronic inflammatory infiltrate, myxoid and focal chondroid areas, characterized by a dermal deposit of amorphous, hyaline and eosinophilic material. The microscopic findings of HSI and FHJ are similar. However, in SIH, there is a deposit of hyaline material, also in other organs, such as: gastrointestinal tract, adrenal glands, bladder, skeletal muscles, thymus and parathyroid. Although many theories have been proposed, there is no consensus on the origin and nature of hyaline material. 1,3,5 The histological picture of gingival fibromatosis is fundamentally the same as that of fibrous hyperplasia. It is characterized by keratinized, hyperplastic stratified squamous epithelial tissue, whose interpapillary ridges are arranged in a digitiform manner with connective tissue (underlying the epithelial tissue) rich in fibroblasts and collagen fibers arranged in various directions (Canavarros et al., in 2001).

The histological aspects of these skin tumors are characteristic and show an abundant, homogeneous and amorphous substance with a chondroid appearance with fibroblastic-type tumor cells immersed in this PAS+ eosinophilic substance. In old lesions, this fundamental substance is abundant and presumably represents a precursor of collagen. Under an electron microscope, spindle cells are fibroblasts with dilated rough endoplasmic reticulum and vacuoles in their cytoplasm, filled with granular or filamentous material.

Treatment of the lesions consists of surgical removal. However, this practice can be mutilating and recurrences are frequent. 1,3,5 Recurrences of gingival hypertrophy seem common every few years, therefore clinical monitoring is necessary (Carranza; Newman, 1987; Genco et al., 1989).

CONCLUSION

This is an article published in Open Access under the CreativeCommons Attribution license, which permits unrestricted use, distribution and reproduction in any medium, as long as the original work is correctly cited.

It can be concluded that there is no definitive treatment for hyaline fibromatosis, where palliative treatments were observed in order to offer a better quality of life to the patient.

REFERENCES

1- Al-Najjadah I, Bang LR, Ghoneim IE, Kanjoor JR. Infantile Systemic Hyalinosis. J Craniofac Surg. 2003; 14:719-723.

two- Muniz ML, Lobo AZC, Machado MCMR, Valente NYS, Kim CA, Lourenço SV, et al. Exuberant Juvenile Hyaline Fibromatosis in Two Patients. Pediatr Dermatol. 2006; 23:458-64. 3-

AMCR branches. Contribution to the Study of Juvenile Hyaline Fibromatosis [Thesis]. Belo Horizonte (MG): Federal University of Minas Gerais; 1994.105 p.

4- Yoo SY, Kim JH, Kang HS, Hwang YS, Kim KJ, Kim IO, et al. Clinical and imaging findings of systemic hyalinosis: two cases presenting with congenital arthrogryposis. Skeletal radiology. 2010;39(6):589- 93

5- Lindvall LE, Kormeili T, Chen E, Ramirez MC, Grum-Tokars V, Glucksman MJ, et al. Infantile systemic hyalinosis: case report and review of the literature. Journal of the American Academy of Dermatology. 2008;58(2):303-7.

6- Antaya RJ, Cajaiba MM, Madri J, Lopez MA, Ramirez MCM, Martignetti JA, et al. Juvenile Hyaline Fibromatosis and Infantile Systemic Hyalinosis Overlap Associated With Novel Mutation in Capillary Morphogenesis protein-2 Gene. Am J Dermatopathol. 2007; 29:99-103.

7- Raeeskarami SR, Aghighi Y, Afshin A, Malek A, Zamani A, Ziaee V. Infantile Systemic Hyalinosis: Report of 17-year Experience. Iranian journal of pediatrics. 2014;24(6):775-8.

8- Cam B, Kurkcu M, Ozturan S, Haytac C, Uguz A, Ogden G. Juvenile hyaline fibromatosis: a case report follow-up after 3 years and a review of the literature. International journal of dermatology. 2015;54(2):217-21.

9- Jaouad IC, Guaoua S, Hajjioui A, Sefiani A. Hyaline fibromatosis syndrome with mutation c.1074delT of the CMG2 gene: a case report. Journal of medical case reports. 2014; 8:291

This is an article published in Open Access under the CreativeCommons Attribution license, which permits unrestricted use, distribution and reproduction in any medium, as long as the original work is correctly cited.