Translated from Portuguese to English - www.onlinedoctranslator.com
ournal O Saber -*Multidisciplinary Scientific Journal Know*
**ISSN: 2675-9128. Sao Paulo-SP.**

# Endogenous whitening in endodontically treated traumatized tooth: a report of experience

*Endogenous whitening in endodontically treated traumatized teeth: an experience report*

**Natalie Vitoriano Guedes da Silva**[1]
**Patrick Rodrigues da Silva**[two]
**Victor Lima Drummond De Castro**

*1 Undergraduate in Dentistry, UNI-BH, 2022. Undergraduate at the University Center of Belo Horizonte, MG. Corresponding author: natalie_vitorianog@hotmail.com*
*2 Undergraduate in Dentistry, UNI-BH, 2022. Graduating from the University Center of Belo Horizonte, MG. Corresponding author: patrick.rsilva18@gmail.com*
*3 Master and Specialist in Endodontics, São Leopoldo MANDIC, Campinas, SP. Adjunct professor at the University Center of Belo Horizonte - UniBH. Belo Horizonte, MG. ORCID: https://orcid.org/0000-0001-5254-4745. Corresponding author: victor_drumond@yahoo.com.br*

Submitted on: 02/20/2023
Approved on: 02/21/2023
Published on: 02/24/2023 DOI
10.51473/ed.al.v3i1.483

***SUMMARY***
*The search for dental aesthetics is increasing considerably nowadays. Teeth with a history of trauma may result in color changes and the need for radical endodontic treatment. Endogenous whitening is an alternative treatment for teeth that have suffered darkening of the visual clinical crown. Whitening techniques present extremely satisfactory results, however, they can present side effects such as external reabsorption when it comes to endogenous whitening. The objective of this work is to present a clinical case in which tooth 21 suffered coronal darkening resulting from trauma and after radical endodontic treatment and endogenous bleaching, a significant improvement in color was obtained. It is concluded that endogenous whitening treatment in endodontically treated traumatized teeth is viable, as long as it is well indicated and the limitations of each case are respected by the professional dentist.*
***Key words:****Endogenous whitening, tooth whitening, dental trauma.*

*ABSTRACT*
*The search for dental aesthetics is increasing considerably nowadays. Teeth with a history of trauma may result in chromatic alteration and the need for radical endodontic treatment. Endogenous whitening is a treatment alternative for teeth that have suffered visual clinical crown darkening. The bleaching techniques present extremely satisfactory results, however, they may present side effects such as external resorption when it comes to endogenous bleaching. The objective of this work is to present a clinical case in which tooth 21 suffered coronal darkening due to trauma and after radical endodontic treatment and endogenous whitening, a significant improvement in color was obtained. We conclude that the endogenous bleaching treatment in traumatized teeth treated endodontically is feasible, as long as it is well indicated and the limitations of each case are respected by the professional dentist.*
*KEYWORDS: Endogenous whitening, tooth whitening, dental trauma*



## 1. INTRODUCTION

Dental trauma is considered by the World Health Organization - WHO - to be an important public health problem worldwide due to its high prevalence rate. Currently the number of cases of teeth

*This is an article published in Open Access under the CreativeCommons Attribution license, which permits unrestricted use, distribution and reproduction in any medium, as long as the original work is correctly cited.*

trauma in young adult patients has grown exponentially (RODRIGUES et al, 2015). According to a study published by Revista Científica Multidisciplinar in 2022, around 62.8% of reported cases of dentoalveolar trauma in Brazil were in adult patients, contradicting historical data that the highest prevalence of this finding used to be in children, mainly in the first three decades of life, justified by the fact that in this age group the child does not yet have complete motor coordination (FIGUEREDO et al, 2022).

The main causes related to dentoalveolar trauma are sports, domestic violence, falls and car accidents. Traumatic injuries to the teeth can cause damage ranging from minimal loss of enamel to tooth avulsion and complex fractures involving the pulp tissue. Most of these fractures require a multidisciplinary approach and the treatment of choice will depend on a series of factors, such as fracture extension, invasion of biological space, presence of pulp exposure, stage of root development, soft tissue injuries, presence of trauma concomitant periodontal disease, presence/ absence of the fractured tooth fragment and its adaptation, occlusion, aesthetics, time and available resources (ANDRIOLO, 2011).

One of the consequences associated with dentoalveolar trauma is pulp necrosis and the need to perform radical endodontic treatment as a way of restoring health and function of the dental element. This approach is generally adopted when there is pulp tissue involvement in the fracture area. Coronary darkening may also be associated with pulp involvement, as it causes damage to the vascular bundle.

- nervous, the bloody content can reach the dentinal tubules, causing a change in the color of the dental element, which sometimes generates aesthetic dissatisfaction, especially when it comes to the anterior dentition (SANABE et al, 2009).

The search for aesthetics in the context of current dentistry has become an object of concern for professional dentists and society. This new perspective has required improvement in techniques and materials with the aim of offering the patient teeth with shape, size, contour, symmetry and coloring of a contemporary standard (CARDOSO et al, 2011).

One of the treatment alternatives to improve the color of endodontically treated traumatized teeth It istooth whitening, whichit is aconservative and low-cost procedure when compared to other color correction methods such as veneers. Whitening techniques present extremely satisfactory results, however, they can present side effects such as external reabsorption when it comes to endogenous whitening (CARVALHO, 2017).

Furthermore, according to Baratieri (1995), the maintenance of long-term results is not predictable, even when the tooth responds favorably to whitening. Since endogenous whitening It isa much requested procedure, with a conservative technique, low cost and with highly satisfactory results, this clinical case report aims to present a clinical case of a traumatized tooth treated endodontically which resulted in the darkening of the clinical crown and the final result was improvement significant in color.

## two . EXPERIENCE REPORT

Patient MFSP, 52 years old, female, attended a private dental clinic complaining of darkening of element 21. During anamnesis, it was reported that the patient suffered a trauma during adolescence, at the time, the patient reported that she hit her mouth on a table. During the various preventive consultations throughout her life, no investigation or guidance had ever been carried out regarding the patient's complaint.

During clinical examination, the absence of signs and symptoms was observed in tooth 21. During palpation and percussion, the tooth did not show any response. The tooth also showed no response to the cold test (Maquira Endo Ice Test Vitality Spray), while the neighboring elements showed positive responses within the standard. Pulp necrosis was concluded and diagnosed without the presence of injury to tooth 21.



*This is an article published in Open Access under the CreativeCommons Attribution license, which permits unrestricted use, distribution and reproduction in any medium, as long as the original work is correctly cited.*

**Figure 1.**Initial appearance of tooth 21 staining



Source: Personal archive

Endodontic treatment of element 21 was proposed and later endogenous and exogenous whitening would be carried out in addition to rehabilitation with composite resin.

**Figure 2.**Initial periapical radiograph of tooth 21



Source: Personal archive

In the first consultation, the endodontic treatment of tooth 21 was planned. In this way, the opening began with a spherical diamond drill 1014 HL and as soon as access to the pulp chamber was gained, then the opening was completed with a frusto-conical diamond drill. idle tip 3082.
Absolute isolation was carried out to continue treatment. Exploration of the canal was performed with a #15 K-file, and odontometry was performed using the apical locator, which confirmed the CT = 21mm. Mechanized instrumentation was performed with Protaper Next (Dentsply) X1, X2 and X3 files. During the entire process, irrigation was carried out with 50ml of 2.5% Sodium Hypochlorite and activation with an Irrisonic ultrasonic insert (HELSE) coupled to an ultrasound with 20% power.
After the entire instrumentation protocol, the final irrigation protocol was carried out to enhance the PQM. 40ml of NaOCl were used, the canal was irrigated with an amount of EDTA that was enough to be activated 3x 30 seconds with ultrasound. Finally, 10ml of hypochlorite was used again and activated with ultrasound. The canal was dried with paper cones.
- Explanation: hypochlorite is used after EDTA, as EDTA deobliterates the dentinal tubules by removing the smear layer, making it possible for better penetration of hypochlorite into the tubules, increasing the cleaning and decontamination.



In the last phase, the filling process was started. The canal was dried with paper cones and filling began. Dentsply's X3 standardized gutta-percha cone was used, following the pattern of the last file that was used in the instrumentation. After testing the cone and checking, the cone was sterilized in NaOCl. The filling cement used was AH Plus (Dentsply). Lateral condensation and vertical compression were performed followed by the use of a McSpadden 25mm #40 gutta-percha condenser.
Finally, the tooth was provisionally sealed with ionoseal (Voco) and sent for the planned aesthetic treatment.

*This is an article published in Open Access under the CreativeCommons Attribution license, which permits unrestricted use, distribution and reproduction in any medium, as long as the original work is correctly cited.*

**Figure 3.**Final radiographic image after formation of the apical obturation plug seen on a periapical radiograph.



Source: Personal archive

After 1 week, the tooth showed no signs and symptoms and then endogenous whitening treatment could be started. The bleaching agent used for endogenous bleaching was Whiteness Super-endo 37% (FGM). 3 sessions were carried out with an interval of 3 days between them.
- Explanation: 3mm of gutta percha was prepared below the cervical level, after removing the gutta percha the tooth was sealed with preparation and sealed with flow resin Bulk Fill SDR Plus Refil Universal (Dentsply).

**Figure 4.**Whitness Super-endo 37% (FGM) whitening gel application process

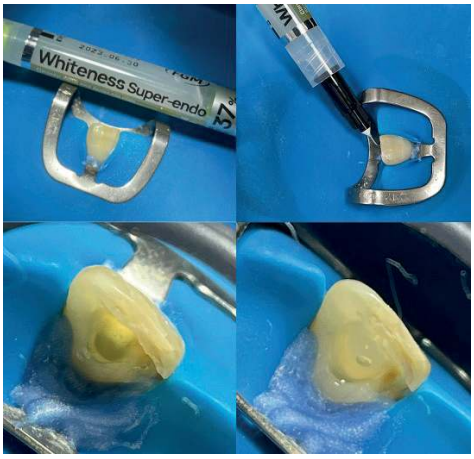


Source: Personal archive

After the last endogenous bleaching session, 1 Whiteness HP 35% (FGM) exogenous bleaching session was performed to finish achieving the appropriate color.
After 1 week of whitening, it was found that the color of tooth 21 was already similar to the adjacent teeth. Then, reconstruction of the tooth with X350 (3M) composite resin was performed. The color of the teeth was measured using the classical A1-D4 color scale (Vita).



*This is an article published in Open Access under the CreativeCommons Attribution license, which permits unrestricted use, distribution and reproduction in any medium, as long as the original work is correctly cited.*

**Figure 5.**Final appearance of tooth 21 color after endogenous and exogenous whitening



Source: Personal archive

## DISCUSSION

Due to its high prevalence, dental trauma is considered a public health problem. Anterior teeth with overjet are the most affected elements (RODRIGUES, 2015). The pulp's reaction to trauma can trigger excessive dentin production, sometimes leading to dental calcification, making endodontic treatment difficult or even unfeasible. This physiological process only stops after pulp necrosis occurs or after endodontic treatment (VAZ et al, 2011).

Dental trauma can cause total or partial disruption of the pulpal vascular-nervous bundle, causing hemorrhage which can lead to darkening of the visual clinical crown of the tooth. The degree of pigmentation varies according to the intensity of the lesion and the time elapsed between the trauma and endodontic treatment. In some cases, coronal pigmentation is accompanied by pulp vitality, which can be explained by the intracellular metabolization of hemoglobinogenic pigments (CONSOLARO; NEUVALD; RIBEIRO, 2005).

Three bleaching agents are currently frequently used: sodium perborate, hydrogen peroxide and carbamide peroxide, which differ in concentrations, mechanism of action and application techniques. The bleaching agent of choice for carrying out the clinical case was 35% carbamide peroxide, which dissociates into 25% urea and 10% hydrogen peroxide. The fact that there is a low concentration of hydrogen peroxide and that urea regulates intracoronary pH makes this whitening agent very beneficial. When there is a low pH inside the crown, an inflammatory reaction is initiated, increasing the chances of establishing an external root resorption process (HARRINGTON; NATKIN, 1979). It is therefore necessary, according to Baratieri (1995), to create a cervical cap with temporary restorative material, which aims to seal areas where there are free spaces close to the cementoenamel junction area. If the cervical portion is not completely sealed, there is a risk of extravasation of the bleaching material, causing external cervical resorption.

Dentin, a constituent part of the dental element, is highly permeable due to its tubular structure and thanks to this permeability it is possible to carry out internal whitening. The mechanism of action of the bleaching agent consists of releasing large quantities of oxygen molecules within the dentinal tubules, which reach the macromolecules adhered to the dentin tissues, generating an oxidation-reduction reaction, removing, through the diffusion process, the pigmented macromolecules from the dental tissues. (DZIERZAK, 1991).

Endogenous whitening is a procedure much sought after by patients who seek to have aesthetics restored as a result of trauma, having the advantage of being a conservative treatment, as it allows for the preservation of dental tissues, considering that the same access as endodontic treatment is used and therefore be low cost compared to other types of treatments. However, literature has disadvantages, since there are high rates of recurrence, and should always be suggested as an attempt at a more conservative (CANUTO et al, 2020).

The dental veneer is an alternative to the recurrence of endogenous whitening to recover darkened and grayish teeth, as it blocks the bottom of the tooth, in addition to the fact that the anatomy is restored by the aesthetic veneers. Even so, veneers have disadvantages because they are not conservative, since for their perfect adaptation, it is necessary to wear the structure of the tooth, in addition to being a higher cost procedure for the patient (BARBOSA et al, 2021).

## CONCLUSION



*This is an article published in Open Access under the CreativeCommons Attribution license, which permits unrestricted use, distribution and reproduction in any medium, as long as the original work is correctly cited.*

The clinical case presented shows that the endogenous whitening technique as an attempt to minimize tooth darkening resulting from traumaIt isviable and can be done successfully if there is adequate management by the dentist.

## REFERENCES

ANDRIOLO, GISELE CRISTINA GALDEANO. Multidisciplinary treatment plan for dental trauma: clinical case report 2011. 20 f. Available at: https://repositorio.unesp.br/bitstream/handle/11449/149398/000846248.pdf?sequence=1. accessed on July 19, 2022.

BARATIERI, Luiz Narciso et al. Nonvital tooth bleaching: guidelines for the clinician. Quintessence International, Berlin, v. 26, no. 9, 1995. p. 597- 608.

BARBOSA, Jatyra Souza; NERES, Anna Luisa Azevedo Dias; Amaral, Saryta Argolo Souza. Direct restorative approach to discolored teeth: literature review. Research, Society and Development, vol. 10, no. 15, e500101523130, 2021

CANUTO, Laryssa Costa. et al. Internal tooth whitening: case report. Electronic Magazine Acervo Saúde, n. 48, p. e3236, May 7, 2020. Available at <https://acervomais.com.br/index.php/saude/article/vie w/3236/1912> accessed on September 29, 2022.

CARDOSO, Renan Menezes; CARDOSO, Randerson Menezes; JUNIOR, Paulo Correia de Melo and MENEZES FILHO, Paulo Fonseca. Internal whitening: an alternative for dyschromia in endodontically treated teeth. Dentistry. Clín.-Scient. (Online) [online]. 2011, vol.10, n.2, pp. 177-180. ISSN 1677-3888.

Carvalho BM Gruendling A. Combined whitening technique in endodontically treated teeth after trauma: case study. Rev. Odontol. Univ. Cid. São Paulo 2017; 29(3): 289-99, Sep-Dec. Available at https://docs.bvsalud.org/biblioref/2018/07/908808/odo nto_03_2017_289-299.pdf accessed on Aug 18, 2022.

CONSOLAR, A.; NEUVALD, L.;RIBEIRO,FC, Tooth whitening: clinical applications and their relationships with tooth resorption. In: CONSOLARO, Alberto. Tooth resorptions in clinical specialties. Maringá: Dental Press, 2005.

DZIERZAK, J. Factors which cause tooth color changes: protocol for in office ''power'' bleaching. Pract Periodontics and Aeshetic Dentistry, Mahwah, NJ, v. 3, no. 2, Mar 1991.

FIGUEREDO M. S; FERRARI T.C; SANTOS, J. P;NEPOMUCENO, AF Occurrence and factors associated with dentoalveolar trauma in Brazil. RECIMA21 - Exact and Earth Sciences, Social, Health, Humanities and Engineering/Technology. v.3, n.7, 2022.

HARRINGTON, GW NATKIN, E., External root resorption associated with bleaching pulp teeth, J Endodon, v. 5, no. 11, Nov, 1979. p. 344-348.

MARTINS, Joana Dourado. et al. Different whitening alternatives for endodontically treated darkened teeth. R. Ci. avg. biol., Salvador, v.8, n.2, p. 213-218, May/Aug. 2009. Available at: https://periodicos.ufba.br/index.php/cmbio/article/view/ 4073/2970> accessed on July 24, 2022.

ROCHA, Marcos Sousa. et al. Endodontic reintervention and endogenous whitening of darkened anterior teeth: case report. Arch Health Invest (2020) 9(2):112-118. Available at: <https://www.archhealthinvestigation.com.br/ArcHI/arti cle/view/4757/pdf> accessed on September 14, 2022.

Rodrigues AS, Castilho T, Antunes LAA, Antunes LS. Epidemiological profile of dental injuries in children and adolescents in Brazil. UNOPAR Cient Ciênc Biol Saúde 2015;17(4):267-78.



*This is an article published in Open Access under the CreativeCommons Attribution license, which permits unrestricted use, distribution and reproduction in any medium, as long as the original work is correctly cited.*

SANABE, Mariane Emi. et al. Emergencies in dental trauma: classification, characteristics and procedures. Rev Paul Pediatr 2009;27(4):447-51. Available at: <https://www.scielo.br/j/rpp/a/zPpVrJJv7LK-T9QQ8M9cpmPG/?lang=pt&format=pdf> accessed on October 18, 2022.

VAZ, Irene Pina. et al. Treatment of upper central incisors after dental trauma. RGO -Rev Gaúcha Odontol., Porto Alegre, v.59, n.2, p.305-311, Apr./Jun., 2011.



*This is an article published in Open Access under the CreativeCommons Attribution license, which permits unrestricted use, distribution and reproduction in any medium, as long as the original work is correctly cited.*