Translated from Portuguese to English - www.onlinedoctranslator.com
ournal O Saber -*Multidisciplinary Scientific Journal Know*
ISSN: 2675-9128. Sao Paulo-SP.

Apexification in teeth with incomplete rhizogenesis: an experience report

Apexification in teeth with incomplete rhizogenesis: an experience report

Agatha Maria Santos Bezerra[1]
Camila Suanine Borba De Moura[two]
Gabrielly Lopes DaSilva Araújo[3]
Karine Ferreira Santos[4]
Nayara Louise Da Silva Dias[5]
Victor Lima Drummond De Castro[6]

Submitted on: 02/20/2023
Approved on: 02/21/2023
Published on: 02/28/2023 DOI
10.51473/ed.al.v3i1.487

1. *Student of Dentistry, UNI-BH, 2022. Student of the University Center of Belo Horizonte, MG. Corresponding author: Agatha Maria Santos Bezerra: agathagreyjoy@gmail.com*
two. *Student of Dentistry, UNI-BH, 2022. Student of the University Center of Belo Horizonte, MG. Corresponding author: suanine.camila@gmail.com*
3. *Student of Dentistry, UNI-BH, 2022. Student of the University Center of Belo Horizonte, MG. Corresponding author: gabriellygaby@yahoo.com.br*
4. *Student of Dentistry, UNI-BH, 2022. Student of the University Center of Belo Horizonte, MG. Corresponding author: karine.ferreira12@outlook.com*
5. *Student of Dentistry, UNI-BH, 2022. Student of the University Center of Belo Horizonte, MG. Corresponding author: naylouise@outlook.com*
6. *Master and Specialist in Endodontics, São Leopoldo MANDIC, Campinas, SP. Adjunct professor at the University Center of Belo Horizonte - UniBH. Belo Horizonte, MG. ORCID: https://orcid.org/0000-0001-5254-4745. Corresponding author: victor_drumond@yahoo.com.br*

SUMMARY
Endodontic treatment in teeth with incomplete rhizogenesis requires special attention due to some characteristics that these teeth may present, such as thin dentin walls, wide root canal and open apex. In these cases, conventional endodontic treatment is not recommended. To this end, it is necessary to carry out a procedure to induce the formation of a mineralized barrier with the help of biocompatible materials, such as calcium hydroxide, mineral trioxide aggregate (MTA) and bioceramic cement (Bio C Repair), called apexification. The objective of this work is to present a clinical case in which, through the apexification technique, the combined technique of calcium hydroxide and Bio C Repair was used, achieving success in the treatment of a tooth with incomplete rhizogenesis and pulp necrosis. It was concluded that apexification treatment in immature teeth is viable, with clinical success with the combination of correct cleaning and disinfection in the root canal, use of good intracanal medication and materials such as calcium hydroxide and Bio C Repair, which will induce formation of mineralized apical barrier.
KEYWORDS: Incomplete rhizogenesis; Bio-C repair; Calcium hydroxide; Apexification.

ABSTRACT
The endodontic treatment in immature teeth requires special attention due to the fragility, thin dentin walls, wide root canal and open apex in this elements. In this cases, the conventional endodontic treatment becomes unfeasible, which lead to a procedure that has the goal by inducing the formation of mineralized barrier by using biologically compatible materials with consistent characteristics, like calcium hydroxide, MTA and bioceramic cement(Bio C Repair), named by apexification. The objective of this research is to present a successful experience of endodontic treatment in an immature teeth with by using the technique apexification with combination of calcium hydroxide and Bio C Repair. It was concluded that the apexification treatment in immature teeths is viable, having clinical success with the combination of a correct cleaning and disinfection in the rooth, the use of good intracanal medication and the use of materials like calcium hydroxide and Bio C Repair, which will induce formation of mineralized apical barrier.
KEYWORDS: Apexification, Immature teeth, Bio C Repair, Calcium Hydroxide.

INTRODUCTION

Root development continues for up to 3 years after tooth eruption until closure of the apical foramen is achieved. When damage occurs to the dental pulp of permanent elements with root formation

This is an article published in Open Access under the CreativeCommons Attribution license, which permits unrestricted use, distribution and reproduction in any medium, as long as the original work is correctly cited.

incomplete, pulp necrosis may occur (SIMON, S.*et al.*2007). Consequently, dentin development and root formation are interrupted, causing this element to have a wide root canal and an open apex, in addition to thin and weakened dentin walls (FELIPPE WT; FELIPPE MCS; ROCHA JC 2006).

The most common cause of pulp necrosis in children is trauma and occurs mainly in upper permanent incisors that have not yet completed their root formation, but it can also occur in teeth with untreated carious lesions (DUGGAL, M.*et al.* 2017; FOUAD, AF 2019). When pulp necrosis occurs in teeth with incomplete rhizogenesis, one of the treatment options is endodontic therapy using a technique called apexification which consists of inducing the formation of a physical barrier of mineralized tissue, considering that in these cases conventional endodontic treatment is makes it unviable due to the large foramen (KRÖLING, AE*et al.*2014). The objective of this procedure is to seal the region of the root apex, removing communication between the root canal and the periapical tissues, in addition to providing a blockage so that the filling material is blocked at the root apex and allows this material to be compacted (AL-KAHTANI , A.*et al.*2005).

Apexification has as standard the use of calcium hydroxide, as it demonstrates a high success rate, playing an important role in this therapy due to some properties it has, such as antibacterial action and its ability to induce the formation of mineralized tissue (GRÜNDLING, GSL*et al.* 2010; REYES, A.D. *et al.*2005).

Some materials have been used in the apexification process, an example is mineral trioxide aggregate (MTA) (BESLOT-NEVEU, A.*et al.* 2011). This material has been proposed as effective for sealing the apex of dental elements with incomplete rhizogenesis that have suffered pulp necrosis. This acts by preventing leakage of the filling material and reduces apical infiltration, being composed of small hydrophilic particles that come together in the presence of moisture (TORABINEJAD, M.; WATSON, TF; PITT-FORD, TR 1993).

The MTA apical plug generates a good apical barrier of mineralized tissue, as it has good sealing properties, providing good apical closure (BODANEZI, A.*et al.* 2009). The use of MTA in the apexification process is becoming widely used and indicated by its high success rates. Furthermore, endodontic treatment has faster resolution with this material (OLIVEIRA, DCRS *et al* . 2011).

MTA has proven characteristics that favor its use in these treatments, such as biocompatibility (LEE, SJ; MONSEF, M.; TORABINEJAD, M. 1993; TORABINEJAD, M.; WATSON, TF; PITT-FORD, TR 1993), good capacity sealing (LEE, SJ; MONSEF, M.; TORABINEJAD, M. 1993), ability to induce formation and deposition of mineralized tissue generating a satisfactory mineralized barrier (FARACO JUNIOR, IM; HOLLAND, R. 2001; TORABINEJAD,M.; WATSON, TF; PITT-FORD, TR 1993), in addition, another advantage of this material is its good radiopacity and its resistance to humidity (TORABINEJAD, M.; WATSON, TF; PITT-FORD, TR 1993).

Another material that has excellent properties and has been widely used in apexification is repair cement.*Bio-C Repair*from the company Angelus (Londrina, PR, Brazil), which has the same applications as the MTA as it has similar characteristics. Furthermore, due to some limitations of the MTA, the*Bio-C Repair*proved to be a bioceramic with considerable advantages, one of which is that this material comes ready to use, with no need for manipulation, thus reducing errors in the consistency of the material and having an easy application (CINTRA, LTA*et al.*2017; PARIROKH, M.; TORABINEJAD, M. 2010).

Another advantage is that a greater amount of zirconia oxide was found in this material, which is a radiopacifier that is directly associated with preventing tooth darkening (LOVATO, KF; SEDGLEY, CM 2011; KOHLI, MR*et al.*2015).

In MTA, the radiopacifier used is bismuth oxide, a material that has been indicated as the main component responsible for tooth darkening (BERGER, T.; BARATZ, AZ; GUTMANN, JL 2014; MARCIANO, MA*et al.*2014; TSATSAS, DV; MELIOU, HA 2005.). The use of zirconia oxide in the composition of*Bio-C Repair*It also has the advantage of increasing its compression resistance (VASQUES-GARCIA, F.*et al.*2016) and also increases its antimicrobial capacity (ESPIR, CG*et al.*2016) and induction of cell proliferation (SILVA,GF*et al.*2017).

The clinical case present in this study shows a satisfactory result in which the apexification technique was used, combining calcium hydroxide and cement.*Bio-C Repair*in teeth with an incompletely formed apex due to pulp necrosis.

This research aimed to present the experience in which successful endodontic treatment was achieved.

This is an article published in Open Access under the CreativeCommons Attribution license, which permits unrestricted use, distribution and reproduction in any medium, as long as the original work is correctly cited.

view of a tooth with incomplete rhizogenesis due to trauma with crown fracture, using the combined technique of apexification with Calcium Hydroxide and *Bio-C Repair.*

EXPERIENCE REPORT

Patient KGFM, 10 years old, female, attended a private dental clinic complaining of exacerbated, spontaneous, diffuse pain that did not cease with medication in the region of element 11. During the anamnesis with the guardian, it was reported that the child suffered a trauma 3 years ago with crown fracture. At the time, they sought dental care, the professional placed the fragment and dismissed the patient. During the clinical examination, the patient reported an increase in donor volume on horizontal and vertical percussion testing and palpation. Slight edema was observed in the region at the bottom of the vestibule. The digital radiographic examination showed that the tooth presented incomplete rhizogenesis, periapical lesion and divergent root walls (Figure 1). From this, the final diagnosis was defined as acute abscess.

Figure 1. Initial periapical radiograph of tooth 11.



Source: Personal archive.

In the first consultation, it was planned to open and drain the purulent exudate. In this way, the opening began with a long-shank 1011 diamond spherical drill.*(KG Sorensen)* and as soon as access to the pulp chamber was gained, spontaneous drainage of the purulent exudate via the canal occurred (Figure 2). Massages were performed on site to help drainage. After a few minutes, the flow of the purulent collection decreased, allowing the opening to be completed with a 3082 inactive tip frusto-conical diamond drill.*(KG Sorensen).*

***F*igure 2**. Coronary opening and drainage of purulent exudate.

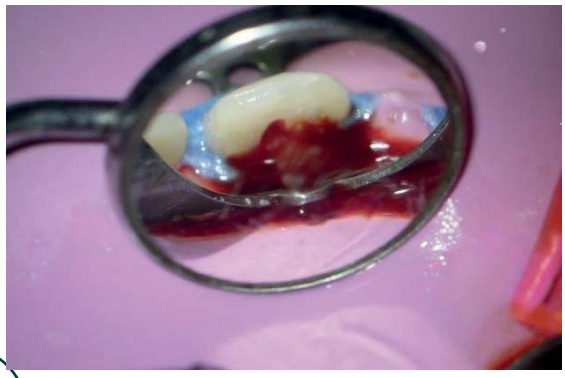

Source: Personal archive.

The canal was not instrumented with files, as the amplitude allowed the "instrumentation" of the canal to be performed with an ultrasonic insert.*Clearsonic (Helse)* coupled to an ultrasound *Newton Booster (Acteon)* at 30% power (Figure 3). As the apex had not yet completely formed, odontometry with an apex locator could lose its accuracy, which is why electronic odontometry was performed and confirmed with radiography (Figure 4).

This is an article published in Open Access under the CreativeCommons Attribution license, which permits unrestricted use, distribution and reproduction in any medium, as long as the original work is correctly cited.

Figure 3. Canal cleaning process with ultrasonic insert coupled to an ultrasound.

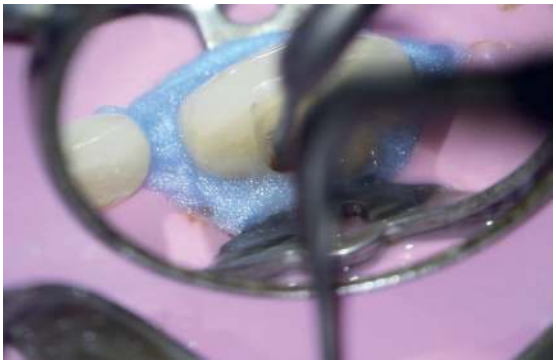

Source: Personal archive

Figure 4. Odontometry periapical radiography



Source: Personal archive

During the entire process, irrigation was carried out with 50 ml of 2.5% sodium hypochlorite and activation with an ultrasonic insert*Clearsonic (Helse)*coupled to an ultrasound with 20% power. As the production of exudate did not cease at the same time as the first intervention, it was decided to place Formocresol (Biodynamics) in a cotton ball as intracanal medication for two days. The tooth was sealed with glass ionomer*Ionoseal (Voco)*.

After two days, the patient returned for the second session, which included removal of the Formocresol and abundant irrigation with 2.5% sodium hypochlorite always activated with ultrasound. After 40 ml of 2.5% sodium hypochlorite, the canal was irrigated with an amount of EDTA (Biodinamic) to remove intracanal dentin shavings, facilitating the action of removing organic matter from the sodium hypochlorite, being activated 3 times 30 seconds with ultrasound. Finally, 10 ml of 2.5% sodium hypochlorite were used again and activated with ultrasound. The canal was dried with absorbent paper cones (Tanari) and ready-made calcium hydroxide paste was inserted*Ultracal XS(Ultradent)*throughout its entire length (Figure 5). Cotton ball in the pulp chamber and sealed with Ionoseal.

Figure 5. Radiographic appearance of intracanal filling with calcium hydroxide seen on a periapical radiograph.



Source: Personal archive.

This is an article published in Open Access under the CreativeCommons Attribution license, which permits unrestricted use, distribution and reproduction in any medium, as long as the original work is correctly cited.

In the third session, after 30 days, all the calcium hydroxide paste was removed from the inside of the canal with ultrasonic tips.*Clearsonic and Irrisonic (Helse)*together with 2.5% sodium hypochlorite. Afterwards, new irrigation was performed with EDTA and 2.5% sodium hypochlorite, both activated 3 times for 30 seconds. The canal was dried with paper cones and filling began.

As the apex was not formed, an apical plug was created with*Bio-C Repair (Angelus)*, bioceramic repair cement. The*Bio-C Repair*inside the channel with MTA port*(angelus),* taken to the apical point and accommodated with inverted paper cones. After creating the apical plug, the canal was obturated with gutta-percha cones.*(Easy)*molded to fill the entire canal and using obturator cement *Bio-C Sealer (Angelus).*

Finally, the tooth was provisionally sealed with Ionoseal and sent for definitive restoration (Figure 6).

Figure 6. Final radiographic image after formation of the apical obturation plug seen on a periapical radiograph.



Source: Personal archive

DISCUSSION

Teeth with an open apex should not be endodontically filled before the apexification process occurs. This step is essential so that there is a barrier to the condensation of the filling material and prevents its leakage (JEERUPHAN, T.*et al*. 2012; KAHLER, B. 2011; TORABINEJAD, M.; WATSON, T. F.; PITT-FORD, TR 1993).

Several factors contribute to the success of this treatment. Cleaning and disinfecting the root canal system are essential to promote an environment conducive to treatment and good clinical results (DIÓ-GENES, A.; RUPAREL, NB 2017; ARSLAN, H.*et al*. 2019).

As the immature dentin walls are thin and fragile (FELIPPE, WT; FELIPPE, MCS; RO-CHA, JC 2006), the use of an ultrasonic insert coupled to an ultrasound becomes efficient for removing debris (RAHDE, N.; GRECCA , F.; BOTTCHER, D. 2012), as wear of the dentin walls must be avoided for molding the canal and mechanical removal of organic matter (LATHAM, J.*et al.*2016). It is extremely important to prioritize efficient irrigation in these cases, in addition to good intracanal medication (KONTAKIOTIS, EG*et al.*2015).

Formocresol is a powerful bactericidal agent and can act both through contact and through vapors released. This is applied to the pulp chamber, neutralizing the septic/necrotic contents of the root canal by diffusing its vapors. It presents a high rate of clinical and radiographic success in pulp treatments, but it does not have been used more because it has toxic properties to tissues (LOPES, HP; SIQUEIRA, JR. 2011).

The concentration of 2.5% sodium hypochlorite has been shown, through several studies, to be the best irrigating solution for removing necrotic and infected tissues (ARSLAN, H.*et al*. 2019; MARTIN, DE *et al*. 2011; KIM, S.G.*et al*. 2018). EDTA has excellent capacity to promote adequate cleaning of the dentin walls so that there are better results from the disinfection of 2.5% sodium hypochlorite through the dentinal tubules (GALLER, KM*et al*. 2016). One of the characteristics that influences the success of endodontic treatment provided by ultrasound is the enhancement of irrigating solutions (PLOTINO, G. *et al*. 2007).

The material recommended as intracanal medication has been calcium hydroxide, due to its anti-inflammatory properties.

This is an article published in Open Access under the CreativeCommons Attribution license, which permits unrestricted use, distribution and reproduction in any medium, as long as the original work is correctly cited.

microbial, in addition to improving root length and thickness of dentin walls, given its ability to induce mineralized tissue formation (BOSE, R.; NUMMIKOSKI, P.; HARGREAVES, K. 2009; CHALA, S.; ABOQAL, R.; RIDA, S. 2011; FARACO JUNIOR, IM; HOLLAND, R. 2001; GRÜNDLING, GSL*et al*. 2010; REYES, A.D.*et al*. 2005).

Calcium hydroxide is a material with significant properties for successful apexification treatment, however, if used without introducing any material that serves as an apical plug, there would be a need for several dressing changes, making the treatment long (AJRAM, J.*et al*. 2019; BESLOT-NE-VEU, A.*et al*. 2011; OLIVEIRA, DCRS*et al*. 2011; REYES, A.D..*et al*. 2005; SOARES, J.*et al*. 2008). In cases of incomplete rhizogenesis and to perform apexification, the use of MTA as an apical plug is considered the first choice for endodontic repair (CHEN, S.*et al*. 2018) leaving the last 3 mm of the root canal as sealed as possible (OLIVEIRA, DCRS*et al*. 2011; REYES, A.D.*et al*. 2005; MESQUI-TA, NV*et al*. 2011). The purpose of MTA as an apical plug is to provide security for the filling process, forming a barrier for the gutta-percha to be condensed (BODANEZI, A.*et al*. 2009; BRITO JÚNIOR, M.*et al*. 2011). However, although it has significant qualities in the treatment of apexification, MTA has some limitations (KOGAN, PHJ; GLICKMAN, GN; WATANABE, I.*et al*. 2006).

In view of the limitations of MTA, bioceramic cements have emerged as an alternative for use as an apical plug (JITARU, S.*et al*. 2016; WALSH, R.M.*et al*. 2018; KAKANI, AK*et al*. 2015). O*Bio-C Repair*is a bioceramic with considerable advantages, being available in ready-to-use form (TOUBES, KS*etal.* 2012). This material provides qualities similar to MTA, differing in terms of practicality in application (CINTRA, LTA*et al.*2017; PARIROKH, M.; TORABINEJAD, M. 2010), prevention of tooth darkening (LOVATO, KF; SEDGLEY, CM 2011; KOHLI, MR*et al.*2015), high antibacterial capacity (ESPIR, CG*et al.* 2016), in addition to inducing cell proliferation (SILVA, GF*et al.*2017). The apical plug is appropriate to resist displacement of the filling material beyond the apex and prevent infiltration of fluids into the canal (OROSCO, FA*et al.*2008).

With the facts exposed, it is possible to observe that clinical success depends on a well-planned step by step and that the*Bio-C Repair*combined with intracanal medication with calcium hydroxide paste provides clinical success for a tooth with an unformed apex, as seen in the clinical case above.

CONCLUSION

The clinical case presented shows that the endodontic technique of apexification in an immature permanent central incisor is viable, and can be performed with clinical success if there is adequate conduct by the dentist, valuing adequate cleaning and disinfection of the root canal system, choice effective intracanal demedications, combined with bioceramic*Bio-C Repair*in the process of inducing mineralized tissue and apical sealing.

REFERENCES

ABBAS, A.*et al*. Efficacy of MTA and Biodentine as Apical Barriers in Immature Permanent Teeth: A Microbiological Study.**Int J Clin Pediatr Dent**. v. 13, n.6, p. 656–662, 2020. Available at: https://www.ijcpd. com/ doi/pdf/10.5005/jp-journals-10005-1853. Accessed on: 02 Apr. 2022.

AGRAFIOTI, A.*et al.*Analysis of clinical studies related to apexification techniques.**European Journal of Pediatric Dentistry**. v. 18, no. 4, p. 273-284, 2017. Available at: https://www.ejpd.eu/pdf/EJPD_2017_4_3. pdf. Access: 15 April. 2022.

AJRAM, J.*et al.*Management of an Immature Necrotic Permanent Molar with Apical Periodontitis Treated by Regenerative Endodontic Protocol Using Calcium Hydroxide and MM-MTA: A Case Report with Two Years Follow Up.**Dentistry Journal**. v. 7, no. 1, 2019. Available at: https://www.mdpi.com/2304-6767/7/1/1/htm. Accessed on: 04 Apr. 2022.

AL–KAHTANI, A.*et al*. In-vitro evaluation of microleakage of an orthograde apical plug of mineral trioxide aggregate in permanent teeth with simulated immature apices.**Jend**. v. 31, no. 2, p.117-119, 2005.

ARSLAN, H.*et al*. Regenerative Endodontic Procedures in Necrotic Mature Teeth with Periapical Radiolucencies: A Preliminary Randomized Clinical Study.**J End.**v. 45, p.863-872, 2019.

BENETTI, F.*et al.*Cytotoxicity, biocompatibility and biomineralization of a new ready-for-use bioceramic repair material.**Braz. Tooth. J.**v. 30, p. 325-332, 2019.

BENETTI, F.*et al.*Cytotoxicity, Biocompatibility and Biomineralization of a New Ready-for-Use Bioceramic

This is an article published in Open Access under the CreativeCommons Attribution license, which permits unrestricted use, distribution and reproduction in any medium, as long as the original work is correctly cited.

Repair Material.**Brazilian Dental Journal.**v. 30, no. 4, p.325-332, 2019. Available at: https://www.scielo. br/j/bdj/a/9HBMghLXV7FHjPNX6LnJqNP/?format=pdf&lang=en. Accessed on: 08 Apr. 2022.

BERGER, T.; BARATZ, AZ; GUTMANN, JL In vitro investigations into the etiology of mineral trioxide tooth staining.**J Conserv Dent.**v. 17, no. 6, p. 526-530, 2014.

BESLOT-NEVEU, A.*et al.*Mineral trioxyde aggregate versus calcium hydroxide in apexification of non vital immature teeth: Study protocol for a randomized controlled trial.**Trials**. v.12, p. 174, 2011.

BODANEZI, A.*et al*. Effects of apical plug on the sealing potential of fillings with mineral trioxide aggregate in teeth with incomplete rhizogenesis.**Rev. Clin. Research Dentistry.**v. 5, no. 3, p. 263- 266, 2009. BOSE, R.; NUMMIKOSK, P.; HARGREAVES, K. A retrospective evaluation of radiographic outcomes in immature teeth with necrotic root canal systems treated with regenerative endodontic procedures.**J. Endod.** v. 35, p.1343-1349, 2009.

BRITO-JÚNIOR, M.*et al.*Clinical evidence of the apexification technique using apical barrier with mineral trioxide aggregate – a critical review.**RFO**. v. 16, no. 1, p. 54-58, 2011.

ĆETENOVIÉ, B.*et al*. Use of mineral trioxide aggregate in the treatment of traumatized teeth in children: Two case reports.**Vojnosanit Pregl**. v. 70, no. 8, p. 781-784, 2013. Available at: http://www.doiserbia.nb.rs/img/doi/0042-8450/2013/0042-84501308781C.pdf. Accessed on: 07 Apr. 2022.

CEVEK, M. Treatment of non-vital permanent incisors with calcium hydroxide. I. Follow-up of periapical repair and apical closure of immature roots.**Odontol Revy.**v.23, p. 27-44, 1972.

CHALA, S.; ABOQAL, R.; RIDA, S. Apexification of immature teeth with calcium hydroxide or mineral trioxide aggregate: systematic review and meta-analysis. Oral Surg. Oral Med. Oral Pathol.**Oral Radiol.Endod.** v.112, n. 4, p. 36 - 42, 2011.

CHEN, S.*et al*. Novel fast-setting mineral trioxide aggregate: its formulation, chemical-physical properties, and cytocompatibility.**ACS Appl Mater Interfaces**. v. 10, p. 20334-20341, 2018.

CINTRA, LTA*et al*. Cytotoxicity, Biocompatibility, and Biomineralization of the New High-plasticity MTA Material.**J End.**v. 43, p. 774-778, 2017.

DIÓGENES, A.; RUPAREL NB Regenerative Endodontic Procedures: Clinical Outcomes.**Dent Clin North Am**. v. 61, p. 111-125, 2017.

DUGGAL, M.*et al*. Interventions for the endodontic management of non-vital traumatised immature permanent anterior teeth in children and adolescents: a systematic review of the evidence and guidelines of the European Academy of Pediatric Dentistry.**Springer**.v. 18, p. 139-151, 2017. Available at: https://link.springer.com/content/pdf/10.1007/s40368-017-0289-5.pdf. Accessed on: 07 Apr. 2022.

ESPIR, CG*et al.*Solubility and bacterial sealing ability of MTA and root-end filling materials.**J Appl Oral Sci.**v. 24, p.121-125, 2016.

FARACO JUNIOR, IM; HOLLAND, R. Response of the pulp of dogs to capping with mineral trioxide aggregate or a calcium hydroxide cement.**Dent. Traumatol**. v. 17, no. 4, p.163-166, 2001.

FELIPPE WT; FELIPPE MCS; ROCHA JC The effect of mineral trioxide aggregate on the apexification and periapical healing of teeth with incomplete root formation.**Int Endd J.**v. 39, n.1, p.2-9, 2006.

FLORATOS, SG*et al*. Apical Barrier Formation After Incomplete Orthograde MTAApical Plug Placement in Teeth with Open Apex: Report of Two Cases.**BrazilianDental Journal.**v. 24, no. 2, p. 163-166, 2013. Available at: https://www.scielo.br/j/bdj/a/RzVxtjZPCZsxvCpPXnWS4dM/?format=pdf&lang=en. Accessed on: 10 April. 2022.

FOUAD, AF Microbiological aspects of traumatic injuries.**Dent Traumatol**. v. 35, p. 324-332, 2019.

GALLER, K.M.*et al.*EDTA conditioning of dentine promotes adhesion, migration and differentiation of dental pulp stem cells.**Int Endd J**. v. 49, p. 581–590, 2016.

GHILOTTI, J.*et al.*Comparative Surface Morphology, Chemical Composition, and Cytocompatibility of Bio-C Repair, Biodentine, and ProRoot MTA on hDPCs.**Materials**. v.13, ed. 9. p. 2189, 2020. Available at: https://mdpi-es.com/d_attachment/materials/materials-3-02189/article_deploy/materials-13-02189-v2. pdf?version=1589279590. Accessed on: 14 April. 2022.

GRÜNDLING, GSL*et al*. Apexification in a tooth with crown-radicular fracture - a case report.**RFO**. v. 15, no. 1, p. 77-82, 2010.

This is an article published in Open Access under the CreativeCommons Attribution license, which permits unrestricted use, distribution and reproduction in any medium, as long as the original work is correctly cited.

GÜNES, B., AYDINBELGE, HA Mineral trioxide aggregate apical plug method for the treatment of nonvital immature permanent maxillary incisors: Three case reports.**Journal of Conservative Dentistry**. v. 15, no. 1, p. 73-76, 2012. Available at: https://www.jcd.org.in/article.asp?issn=0972-0707;year=2012;volume=15;issue=1;spage=73;epage =76;aulast=G%FCnes. Accessed on: 12 April. 2022.

INADA, RMH**Analysis of color changes promoted by repair materials and endodontic cements**The **calcium silicate base with different radiopacifiers.**2018. Dissertation (Masters in Endodontics) - Faculty of Dentistry, Universidade Estadual Paulista, Araraquara, 2018. Available at: https://repositorio.unesp.br/bitstream/handle/11449/15 3833/inada_rnh_me_arafo_par.pdf;jsessionid=9D298E3E - F361F34404E39FBE5D50179C?sequence=5.Accessed on: 11 Apr. 2022.

KONTAKIOTIS, E.G.*et al.*Regenerative endodontic therapy: a data analysis of clinical protocols.**J Ended**. v. 41, p. 146-154, 2015.

KRÖLING, A.E.*et al*. Use of MTA in teeth with incomplete root formation or open foramina: introduction of a protocol and report of clinical cases.**RGO, Rev Gaúch Odontol**. Porto Alegre, vol. 62, no. 3, p. 325-330, 2014. Available at: https://www.scielo.br/j/rgo/a/Nsk5DWZkqJFpGSpZT3nDWXH/?format=pdf&lang=en. Accessed on: 14 April. 2022.

LATHAM, J.*et al.*Disinfection Efficacy of Current Regenerative Endodontic Protocols in Simulated Necrotic Immature Permanent Teeth.**J Ended.**v. 42, p.1218-1225, 2016.

JEERUPHAN, T.*et al.*Mahidol study 1: comparison of radiographic and survival outcomes of immature teeth treated with either regenerative endodontic or apexification methods: a retrospective study.**J. Endod.**v. 38, no. 10, p.1330-1336, 2012.

JITARU, S.*et al*. The use of bioceramics in endodontics - literature review.**Clujul Med**. v. 89, p. 470-473, 2016.

KAHLER, B. Endodontic retreatment of maxillary incisors previously treated with a conventional apexification protocol: a case report. Aust.**Endod. J**. v. 37, no. 1, p. 31-35, 2011.

KAKANI, AK*et al*. A review on perforation repair materials.**J Clin Diagnosis Res**. v. 9, p. 09-13. 2015.

KIM, S.G.*et al.*Regenerative endodontics: A comprehensive review.**Int Endd J**. v. 51, p. 367-1388, 2018.

KOGAN, PHJ; GLICKMAN, G.N.; WATANABE, I. The effects of various additives on setting properties of MTA.**J Ended**. v. 32, p. 569-572, 2006.

KOHLI, M.R.*et al.*Spectrophotometric analysis of coronal tooth discoloration induced by various bioceramic cements and other endodontic materials.**J Ended.**v. 41, p. 1862-1866, 2015.

LEE, SJ; MONSEF, M.; TORABINEJAD, M. Sealing ability of a mineral trioxide aggregate for repair of lateral root perforations.**J. Endod.**v. 19, no. 11, p. 541-544, 1993.

LOPES, HP; SIQUEIRA JR.**Endodontics. Biology and technique.**Rio de Janeiro: MEDSI, 2011.

LOVATO, KF; SEDGLEY CM Antibacterial activity of endosequence root repair material and proroot MTA against clinical isolates of Enterococcus faecalis.**J Ended.**v. 37, p. 1542-1546, 2011.

MANIGLIA-FERREIRA, C.*et al*. 12-Year Follow-Up of Regenerative Endodontic Treatment of Immature Permanent Upper Incisors with Acute Abscess.**Brazilian Dental Journal**. v. 31, no. 6, p. 680-684, 2020. Available at: https://www.scielo.br/j/bdj/a/rkvYGqRyQwQDRFRzv6RJGyD/?format=pdf&lang=en. Accessed on: 18 April. 2022.

MARCIANO, MA*et al*. Assessment of color stability ofwhite mineral trioxide aggregate angelus and bismuth oxide in contact with tooth structure.**J Endod**. v. 40, no. 8, pp.1235–1240.

MARTIN, DE*et al*. Concentration-dependent effect of sodium hypochloride on stem cells of apical papilla survival and differentiation.**J. Endod.**v. 40, p. 51-55, 2014.

MOSQUE, NV*et al.*Apexification of an avulsed tooth using MTA: case report.**Rev. Fac. Odontol**. Porto Alegre. v. 52, no. 1, p. 67-71, 2011.

MORO, EP; KOZLOWSKI JUNIOR, VA; ALVES. FBT Apexification with calcium hydroxide or mineral trioxide aggregate: systematic review.**Rev Odontol UNESP**. v. 42, no. 4, p. 310-316. 2013. Available at: https://www.scielo.br/j/rounesp/a/5sc7tmbB5Zjfc6MVN h8bqzS/?format=pdf&lang=pt. Accessed on: 17 April. 2022.

NIEDERMAIER, KC; GUERISOLI, DMZ Apexification with MTA apical plug in a traumatized tooth.

This is an article published in Open Access under the CreativeCommons Attribution license, which permits unrestricted use, distribution and reproduction in any medium, as long as the original work is correctly cited.

Rev. bras. odontol., Rio de Janeiro, v. 70, no. 2, p. 213-215, 2013. Available at: http://revodonto.bvsalud. org/pdf/rbo/v70n2/a24v70n2.p df. Accessed on: 17 April. 2022.

OLIVEIRA, CTS*et al*. Mineral trioxide aggregate for Intruded Teeth with Incomplete Apex Formation. **Bull Tokyo Dent Cool**. v. 59, no. 1, p. 35-41, 2017. Available at: https://www.jstage.jst.go.jp/article/tdcpublication/59/1/59_2017-0002/_pdf/-char/en. Accessed on: 19 April. 2022.

OLIVEIRA, DCRS*et al.*Evaluation of the use of MTA as an apical plug in teeth with open apices. **Rev. Bras. Dentistry.**Rio de Janeiro. v. 68, no. 1, p. 59- 63, 2011.

OROSCO, FA*et al.*Sealing ability of gray MTAAngelusTM, CPMTM and MBPC used as apical plugs.**J Appl Oral Sci**. v. 16, p. 50-54, 2008.

OROSCO, FA*et al*. Sealing ability, marginal adaptation and their correlation using three root-end filling materials as apical plugs.**J Appl Oral Sci**. v. 18, no. 2, p. 127-134, 2009. Available at: https://www.scielo. br/j/jaos/a/8cJLWFX6PsNsdKtzgvzsBcw/?format=pdf&lang=en. Accessed on: 07 Apr. 2022.

PARIROK, M.; TORABINEJAD, M. Mineral trioxide aggregate: a comprehensive literature review-part III: clinical applications, drawbacks, and mechanism of action.**J Ended.**v. 36, p. 400-413, 2010.

PLOTINO, G.*et al*. Ultrasonics in Endodontics: a Review of the Literature.**Journal of Endodontics**. v. 33, no. 2, p.81-95, 2007.

RAHDE, N.; GRECCA, F.; BOTTCHER, D. Calcium hydroxide removal: effectiveness of ultrasonic and manual techniques.**dentistry,**2012.

REYES, A.D.*et al.*Study of calcium hydroxide apexification in 26 young permanent incisors.**Dent. Traumatol.**v. 21, no. 3, p.141-145, 2005.

SIMON, S.*et al*. The use of mineral trioxide aggregate in one-visit apexification treatment: A prospective study. **Int Endd J**. v. 40, p.186-97, 2007.

SILVA, G. F.*et al.*Zirconium oxide and niobium oxide used as radiopacifiers in a calcium silicate-based material stimulate fibroblast proliferation and collagen formation.**Int Endd J.**v. 50, no. 2, p. 95-108, 2017.

SOARES, J.*et al*. Calcium hydroxide induced apexification with apical root development: a clinical case report. **Int. Endod. J**. v. 4, no. 8, p. 710-719, 2008.

SOUZA, MA*et al.*Mineral trioxide aggregate as apical sealing material in teeth with incomplete rhizogenesis: a case series.**Rev Odonto Cienc**. v. 26, no. 3, p. 262-266, 2011. Available at: https://www.scielo.br/j/roc/a/Z9hmqVqfZ6b5RbrQ8fZk7 ZR/?format=pdf&lang=en. Accessed on: 09 Apr. 2022.

TORABINEJAD, M.; WATSON, T. F.; PITT FORD TR Sealing ability of a mineral trioxide aggregate when used as a root end filling material.**J Ended**. v. 19, p. 591-595, 1993.

TOUBES, K.S.*et al.*Bio-C Repair - A New Bioceramic Material for Root Perforation Management: Two Case Reports.**Brazilian Dental Journal.**v.32, n. 1, p. 104-110, 2021. Available at: https://www.scielo. br/j/bdj/a/dVYsBBcjY53bNQVW9hc 4qmm/?format=pdf&lang=en. Accessed on: 18 April. 2022.

TREVINO, E.G.*et al*. Effect of irrigants on the survival of human stem cells of the apical papilla in a platelet-rich plasma scaffold in human root tips.**J. Endod**.v. 37, p. 1109-1115, 2011.

TSATSAS, DV; MELIOU, HA Sealing effectiveness of materials used in furcation perforation in vitro.**Int Dent J**. v. 55, no. 3, p. 133-341, 2005.

VASQUES-GARCIA, F.*et al*. Effect of silver nanoparticles on physicochemical and antibacterial properties of calcium silicate cements.**Braz Dent J.**v. 27, p. 508-514, 2016.

WALSH, R.M.*et al*. Bioactive endodontic materials for everyday use: a review.**Gen Dent**. v. 66, p. 48-51, 2018.

This is an article published in Open Access under the CreativeCommons Attribution license, which permits unrestricted use, distribution and reproduction in any medium, as long as the original work is correctly cited.