Translated from Portuguese to English - www.onlinedoctranslator.com
ific Journal O Saber.
ISSN: 2675-9128. Sao Paulo-SP.

Year III, v.3, ed. 1, Jan./Jul. 2023. DOI: 10.51473/ed.al.v3i1.586 | submission: 07/14/2023 | accepted: 07/15/2023 | publication: 07/21/2023

Giant incisional hernia and use of multiple associated techniques: case report

Giant incisional hernia and use of multiple associated techniques: case report

Vinicius Souza Nunes
Resident Doctor in General Surgery Medicine at the Higher School of Health Sciences (ESCS) Email: vsnvinicius1994@gmail.com

SUMMARY
The correction of giant incisional hernias with loss of domicile has become an increasingly evident focus of study, given that this complication is present in approximately 11% of laparotomies. Despite the high incidence, it remains an important technical difficulty for surgeons, due to the large number of possible complications, including early dehiscence, compartment syndrome and the impossibility of closure. In this context, preoperative pneumoperitoneum is an option for better visceral accommodation with fewer complications. **Goal:**Report a case of a patient treated surgically for a giant incisional hernia. **Materials and methods:**An observational, single-arm study is proposed, with data collection from the research participant's electronic medical record. The electronic medical record in the TrakCare system is available in all institutions of the Health Department of the Federal District. **Expected results:**The results are expected to disseminate information that helps surgeons with clinical information that allows for prior treatment and improves the quality of life of patients with giant incisional hernias.
Keywords: Incisional hernia, abdominal wall, surgical intervention.

INTRODUCTION

Incisional hernia can be described as a failure of the abdominal wall at the site of closure of the abdominal wall, it is formed from a previous physiological incision, generally occurring as a result of a previous surgical incision that did not heal properly, being more common in the midline of the abdomen. The hernia is considered giant when the protuberance reaches a diameter of more than 10 cm. These can be very painful and impede the individual's daily activities (ABDELHALIM, RADWAN,*et al.*, 2022; SEKHAR, EKKA,*et al.*, 2023; TANSAWET, NUMTHAVAJ,*et al.*, 2022).

Incisional hernia is one of the main determinants of surgical morbidity worldwide, with an incidence between 2% and 20% (SEKHAR, EKKA,*et al.*, 2023; SMITH, MEGGY,*et al.*, 2022).The occurrence of this condition varies depending on the population served and the type of abdominal surgery performed. Studies show that the general incidence of incisional hernias after abdominal surgery varies between 10% and 23%, with the majority of these hernias being small and asymptomatic (MÜLLER, WEYHE,*et al.*, 2023).

Post-laparotomy incisional hernias are associated with inadequate healing of the abdominal fascia. Inadequate healing of the fascia may be due to several factors, such as the surgical technique and the patient's biological factors (KORKUT, AKSUNGUR,*et al.*, 2022). In cases of giant incisional hernia, the incidence is relatively rare, corresponding to less than 1% of all cases (ABDELHALIM, RADWAN,*et al.*, 2022; SEKHAR, EKKA,*et al.*, 2023; TANSAWET, NUMTHAVAJ,*et al.*, 2022; MÜLLER, WEYHE,*et al.*, 2023).

Incisional hernias are divided into small, when their diameter is less than 5 cm, medium with diameters between 5 and 10 cm and large ones with diameters between 10 and 15 cm in width or length. to, and in cases with a diameter greater than 15 cm they are already considered giants. However, many studies define diameters greater than 10 cm as giant incisional hernias (KORKUT, AKSUNGUR,*et al.*, 2022; MÜLLER, WEYHE,*et al.*, 2023).

The potential risk for developing this condition is high in individuals of advanced age, obesity, smokers, diabetics, those with chronic respiratory pathologies or those who have experienced an infection at the site of the surgical incision. Furthermore, the extent and location of the surgical incision pose a strong risk to its development. However, individuals with a giant incisional hernia are at greater risk of discomfort caused by pain, intestinal obstruction may occur,

This is an article published in Open Access under the CreativeCommons Attribution license, which permits unrestricted use, distribution and reproduction in any medium, as long as the original work is correctly cited.

ischemia, infection and reduction in quality of life (MÜLLER, WEYHE,*et al.*, 2023; SMITH, MEGGY,*et al.*, 2022).

The main functions of the abdominal wall are to provide mechanical support to internal structures and intra-abdominal pressure and to promote trunk mobility/movement. Incisional hernias impair the mechanical functions of the abdominal wall, contributing to the occurrence of symptoms such as pain, swelling, nausea, vomiting and constipation (ABDELHALIM, RADWAN,*et al.*, 2022). The diagnosis is guided by physical and complementary imaging exams (ultrasound, computed tomography or magnetic resonance imaging). Therapy consists of using abdominal support, dietary changes, weight loss and physiotherapy to strengthen the abdominal muscles. However, in some more advanced cases, corrective surgery is necessary (LUAN, CAO,*et al.*, 2022; SEKHAR, EKKA,*et al.*, 2023; TANSAWET, NUMTHAVAJ,*et al.*, 2022). The surgical management of incisional hernias is a major challenge for surgeons due to the high rate of complications. Represented by surgical site infection (originating from the mesh, wound dehiscence, seroma and intestinal injury) and recurrence are complications reported in the literature after incisional hernia repair (BACO and MITRIC, 2022; KORKUT, AKSUNGUR,*et al.*, 2022; SHEIKH, ASUNRAMU,*et al.*, 2022; SMITH, MEGGY,*et al.*, 2022; WILLEMIN, SCHAFFER,*et al.*, 2023). Surgical techniques for incisional hernia repair carry a potential risk of abdominal muscle weakness, and postoperative rehabilitation should be considered to rebuild normal muscle strength (ABDELHALIM, RADWAN, *et al.*, 2022; BACO and MITRIC, 2022). In view of the above, the development of the following study aimed toreport a case of a patient treated surgically for a giant incisional hernia, justifying its publication, due to the rarity of this type of case. Furthermore, the information contained in the case report may be useful for clinical justification and assist in the prior treatment of these patients.

CASE REPORT

Male patient, 34 years old, with no known comorbidities or allergies, smoker and cocaine user, was admitted to the Paranoá Regional Hospital in December 2018, victim of a stab wound to his right flank.

After undergoing an exploratory laparotomy, two lesions were identified in the distal ileum without loss of substance and with diameters less than 50% of the circumference of the loop (requirements for treatment without enterectomy), and enterorrhaphy of the lesions was performed.

A patient with hemodynamic instability in the immediate postoperative period, having remained in the ICU for the period necessary for stabilization, still presented in the ICU with partial dehiscence of the aponeurotic wall, and due to the patient's instability, it was decided to undergo correction at a more appropriate time.

Approximately one year after the release of the patient with an incisional wall hernia, he returns to the service to schedule surgical correction due to a giant incisional hernia with a hernia ring measuring (20 x 15 cm). After undergoing a multidisciplinary health assessment with the establishment of specific goals, which the nutritionist recommended weight loss; the cardiologist did not mention any contraindications, but with pharmacological measures for VTE in the postoperative period; pulmonology also had no contraindications to the procedure, only advising on care with progressive pneumoperitoneum and, subsequently, measuring IAP (intra-abdominal pressure) intraoperatively.

After performing a tomography of the abdomen without contrast, approximate measurements were taken of the volume of the hernia (content outside the limits of the abdominal wall) compared to the volume of the intra-abdominal cavity. In this evaluation, the hernial volume represented more than 20% of the volume of the internal cavity, which suggests, according to the literature, that it confers a greater propensity for hypertension abdominal pain, respiratory restriction, among other complications.

We chose to implant an intraperitoneal catheter to perform pneumoperitoneum with daily insufflation until surgery was possible. After the seventh day of follow-up, an incisional hernioplasty was performed using the surgical technique of component separation and implantation of an In Lay polypropylene mesh.

Postoperatively, the patient presented a favorable and uneventful evolution, being discharged with serial evaluations for a period of one year. The patient remained stable and the abdominal hernia did not return, with an important aesthetic appearance.

This is an article published in Open Access under the CreativeCommons Attribution license, which permits unrestricted use, distribution and reproduction in any medium, as long as the original work is correctly cited.

He demonstrated good postoperative results, being discharged from the hospital with outpatient follow-up for one year with complete resolution of the hernia, maintaining the integrity of the abdominal wall.

DISCUSSION

The correction of giant incisional hernias with loss of abdominal integrity has become an increasingly evident focus of study, given that this complication is present in approximately 11% of laparotomies. Although the pneumoperitoneum procedure does not yet have well-established technical protocols regarding how to perform it (volume insufflated, number of days of insufflation), it has proven to be a very effective technique alone or in combination with other techniques for adjusting incisional hernias. . Abdominal insufflation, while generating muscle and abdominal fascia relaxation, can also be considered as a test of the patient's lung capacity, since patients who develop respiratory discomfort solely with insufflation would probably be unable to withstand the occlusion of the abdominal wall. In the present case, the patient did not experience any type of respiratory discomfort. Despite the high incidence of incisional hernias, this continues to be an important technical difficulty for surgeons, due to the large percentage of possible complications, including: early dehiscence, compartment syndrome and the impossibility of closure. In this context, the technique of using pneumoperitoneum to relax abdominal muscles shows promise in advancing corrections of giant incisional hernias, reducing the number of complications and complications as it allows better visceral accommodation.

IMAGES

FIGURE 1–Midline incisional hernia



This is an article published in Open Access under the CreativeCommons Attribution license, which permits unrestricted use, distribution and reproduction in any medium, as long as the original work is correctly cited.

This is an article published in Open Access under the CreativeCommons Attribution license, which permits unrestricted use, distribution and reproduction in any medium, as long as the original work is correctly cited.

FIGURE 2 –Pre-installation preparation of the pneumoperitoneum catheter



FIGURE 3 –Tissue and intra-abdominal space gain after 14 days of progressive Pneumoperitoneum



FIGURE 4 –Closure of the posterior abdominal wall

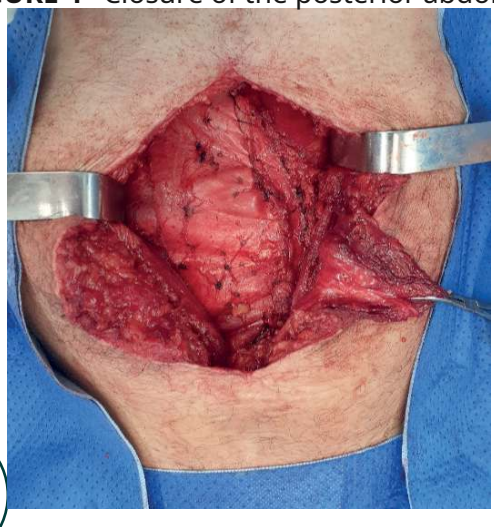

This is an article published in Open Access under the CreativeCommons Attribution license, which permits unrestricted use, distribution and reproduction in any medium, as long as the original work is correctly cited.

FIGURE 5 –Installation of the polypropylene mesh in the retro-muscular space

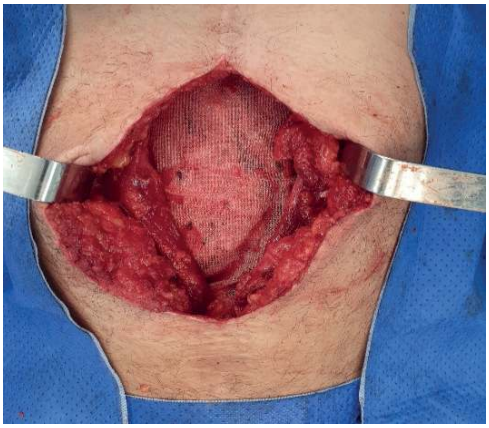

FIGURE 6 AND 7 –Immediate post-operative





REFERENCES

ABDELHALIM, NM et al. The efficacy of isokinetic strength training versus core stability training on the trunk muscle strength and quality of life after surgical repair of incisional hernia in adolescents. Turk J Phys Med Rehabil, v. 68, no. 4, p. 501–508, 2022.

BACCO, ; MITRIC,. Transversus Abdominis Muscle Release in Giant Incisional Hernia. Cureus, vol. 14, no. 8, p. 28277, 2022.

KORKUT, et al. Comparison of Surgical Treatment Results of Large Incisional Hernias. Cureus, vol. 14, no. 11, p. 32020, 2022.

This is an article published in Open Access under the CreativeCommons Attribution license, which permits unrestricted use, distribution and reproduction in any medium, as long as the original work is correctly cited.

LUAN, et al. Construction and properties of the silk fibroin and polypropylene composite biological mesh for abdominal incisional hernia repair. Front Bioeng Biotechnol., v. 10, no. 1, p. 949917, 2022. MÜLLER, et al. Prophylactic effect of retromuscular mesh placement during loop ileostomy closure on incisional hernia incidence—a multicenter randomized patient- and observer-blind trial (PELION trial). Trials, vol. 24, no. 1, p. 76, 2023.

SEKHAR, et al. Effect of Suture Length on the Incidence of Incisional Hernia and Surgical Site Infection in Patients Undergoing Midline Laparotomy: A Systematic Review and Meta-Analysis. Cureus, vol. 15, no. 2, p. 34840, 2023.

SHEIKH, et al. A Cost-Utility Analysis of Mesh Prophylaxis in the Prevention of Incisional Hernias Following Stoma Closure Surgery. Int J Environ Res Public Health., v. 19, no. 20, p. 13553, 2022. SMITH, et al. Incisional hernia prevention: risk–benefit from a patient perspective (INVITE) – protocol for a single-centre, mixed-methods, cross-sectional study aiming to determine if using prophylactic mesh in incisional herniationThe prevention is acceptable to patients. BMJ Open, vol. 12, no. 12, p. 069568, 2022. TANSAWET, et al. Fascial Dehiscence and Incisional Hernia Prediction Models: A Systematic Review and Meta-analysis. World J Surg., v. 46, no. 12, p. 2984–2995, 2022.

WILLEMIN, et al. Drain Versus No Drain in Open Mesh Repair for Incisional Hernia, Results of a Prospective Randomized Controlled Trial. World J Surg., v. 47, no. 2, p. 461–468, 2023. BernardC,etal-Repair of giant abdominal wall hernias using open intraperitoneal mesh Hernia (2007). Minossi, JoséGuilhermeetal.The use of progressive pneumoperitoneum in the preoperative period of large hernias of the abdominal wall. Archives of Gastroenterology, v.46, n.2, p.121-126,20095-320.

This is an article published in Open Access under the CreativeCommons Attribution license, which permits unrestricted use, distribution and reproduction in any medium, as long as the original work is correctly cited.